



# Clinical case

Talitha Borges Aguiar, MD

Retina and Vitreous Fellowship

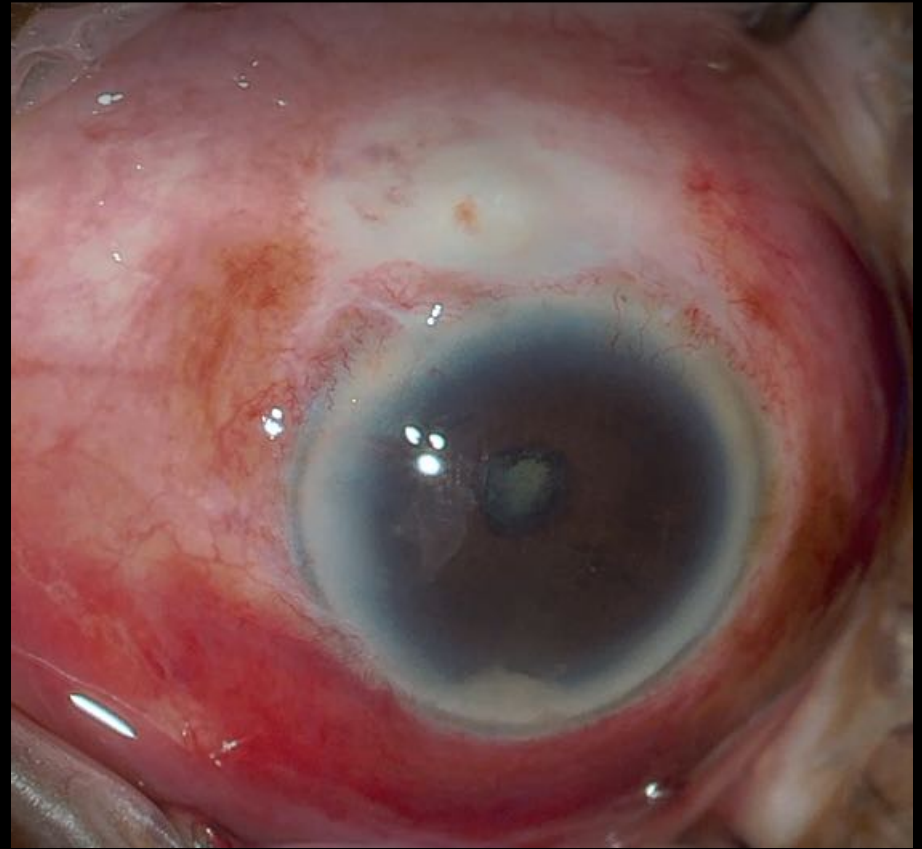
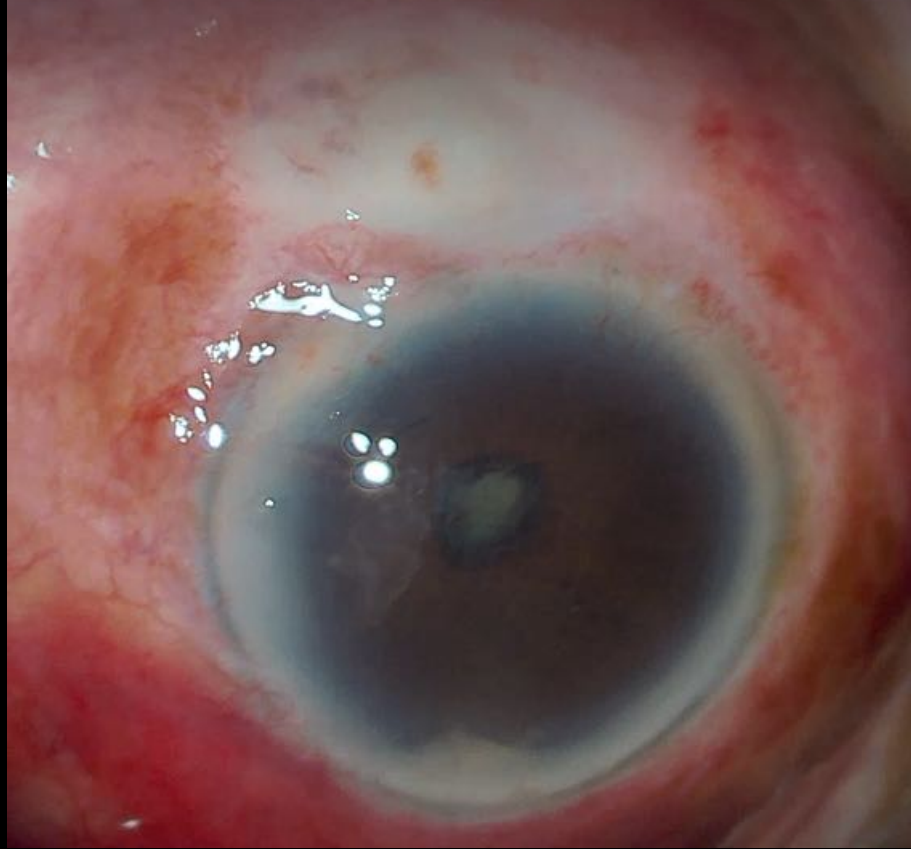
- Pain and sudden vision loss in OS for the past 2 days. Was referred by the Glaucoma division after Intravitreal Injection of dexamethasone, vancomycin and ceftazidime.
- POHx: Advanced glaucoma.
  - Trabeculectomy OU (2016).
  - Pseudophakic OD.
- PMHx: Systemic arterial hypertension.

VA OD: 0,1

OS: LP

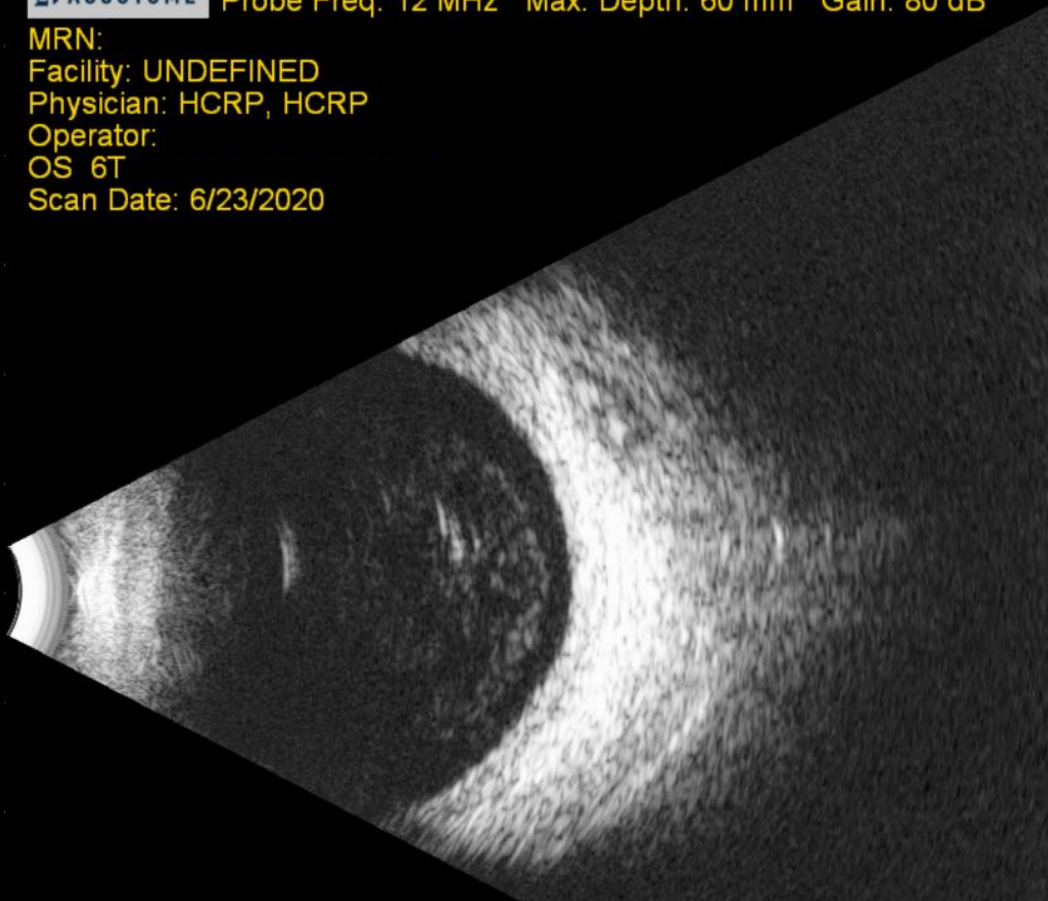
Slit lamp exam OD: Avascular elevated bleb, no seidel, clear cornea, normal depth anterior chamber with no cells, pseudophakic

Slit lamp exam OS: Conjunctival hyperemia with ciliary injection, avascular elevated bleb, with white purulent content, corneal edema, normal depth anterior chamber, hypopyon, pupillary membrane, cataract



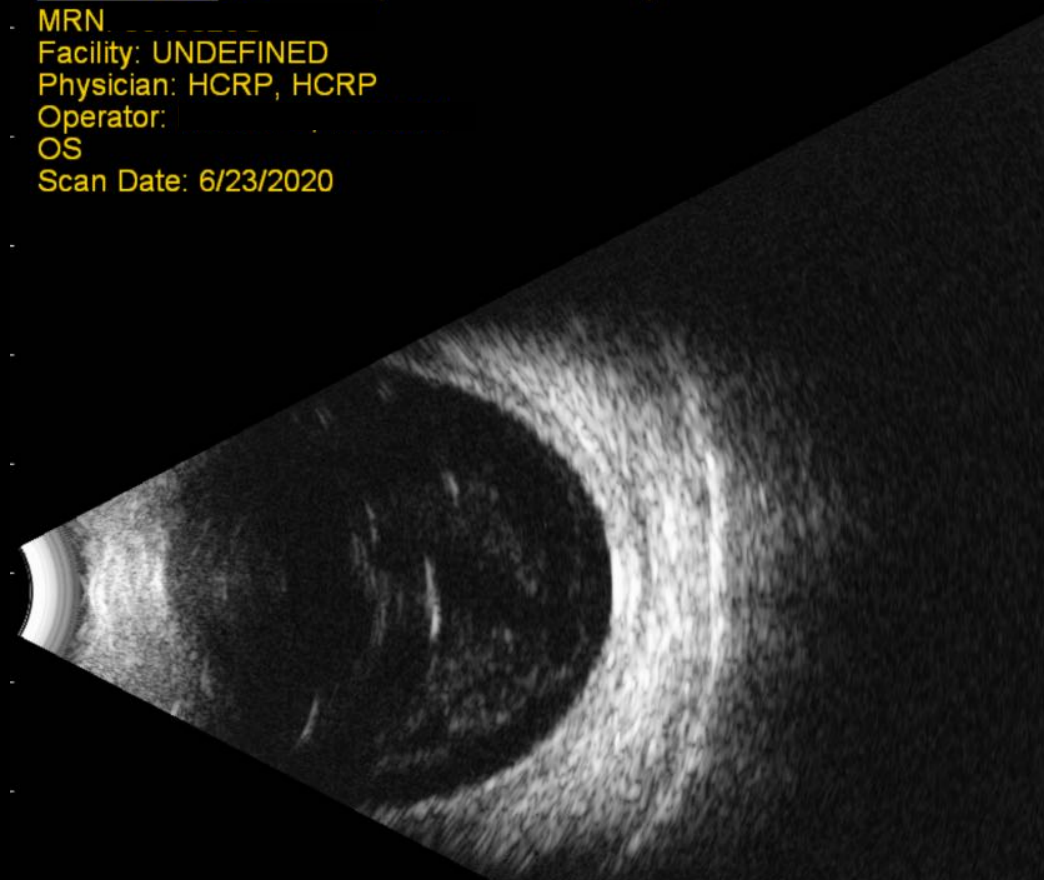
ACCUTOME Probe Freq: 12 MHz Max. Depth: 60 mm Gain: 80 dB

MRN:  
Facility: UNDEFINED  
Physician: HCRP, HCRP  
Operator:  
OS 6T  
Scan Date: 6/23/2020



ACCUTOME Probe Freq: 12 MHz Max. Depth: 60 mm Gain: 76 dB

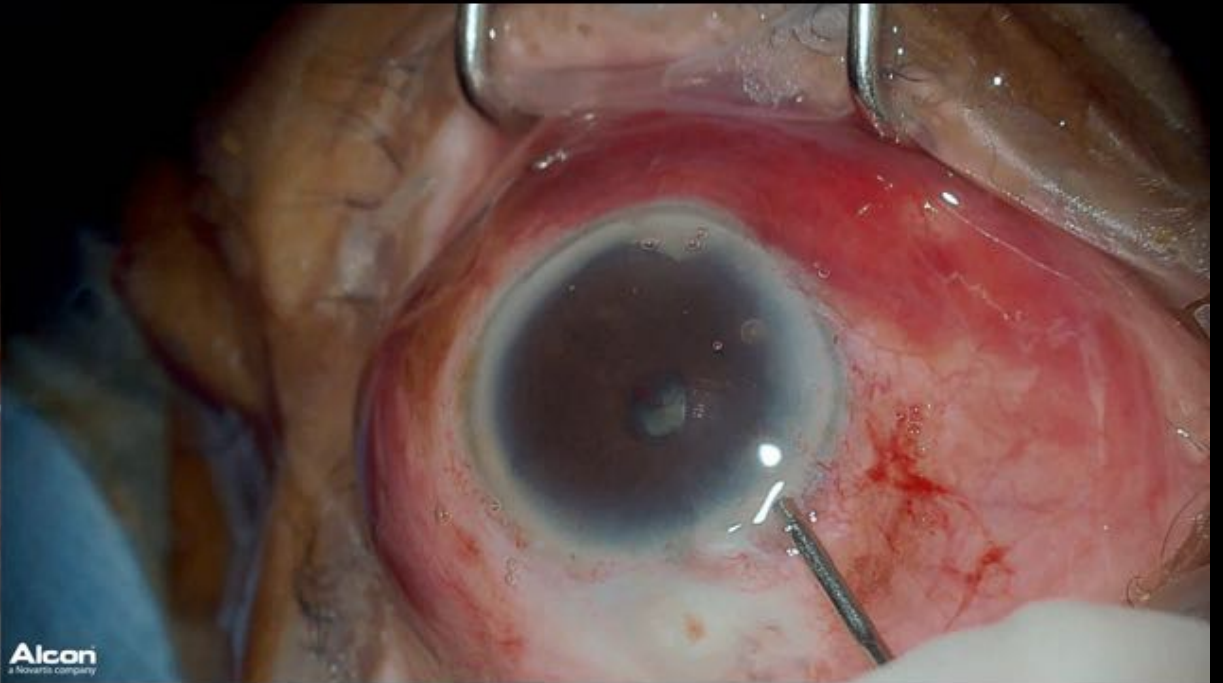
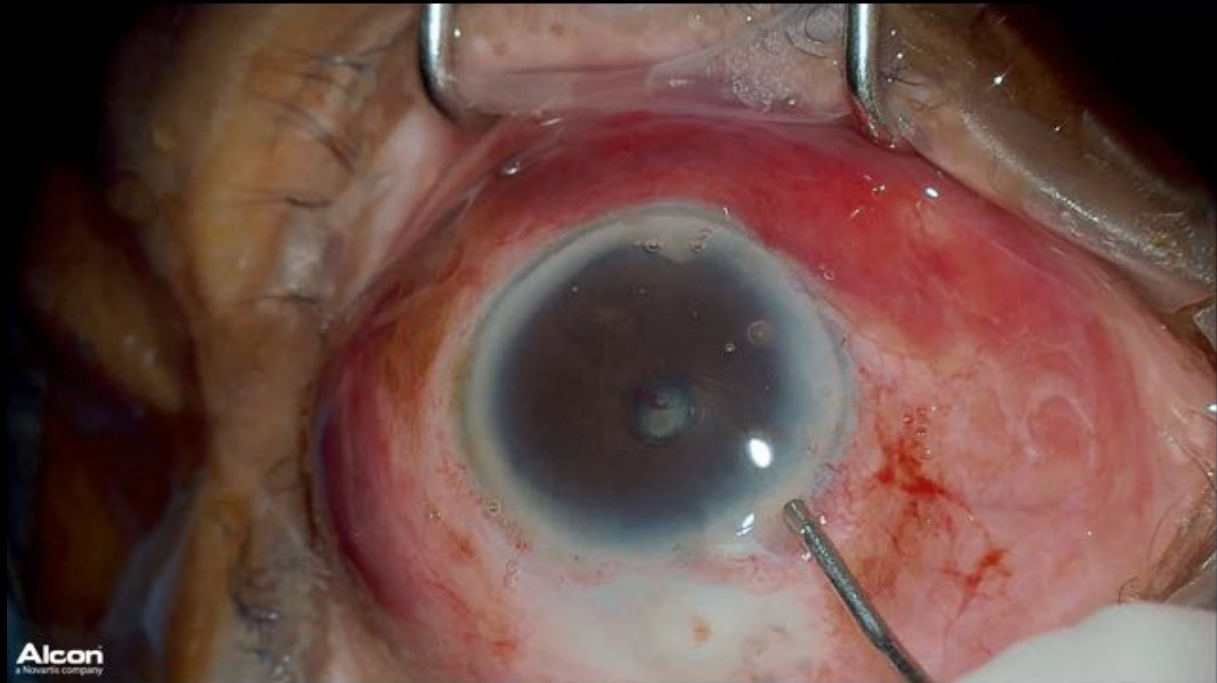
MRN:  
Facility: UNDEFINED  
Physician: HCRP, HCRP  
Operator:  
OS  
Scan Date: 6/23/2020



# Endophthalmitis sec Blebitis

Management: Vitrectomy





14<sup>th</sup> Post-Op

No pain. Reports improvement of VA.

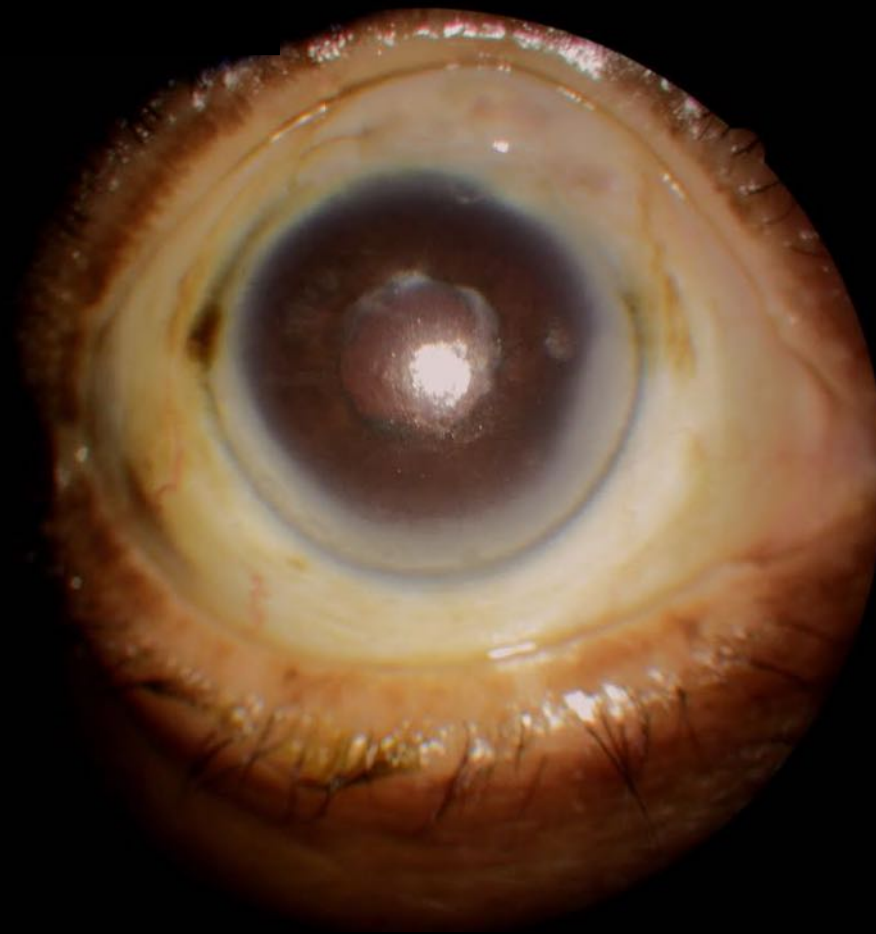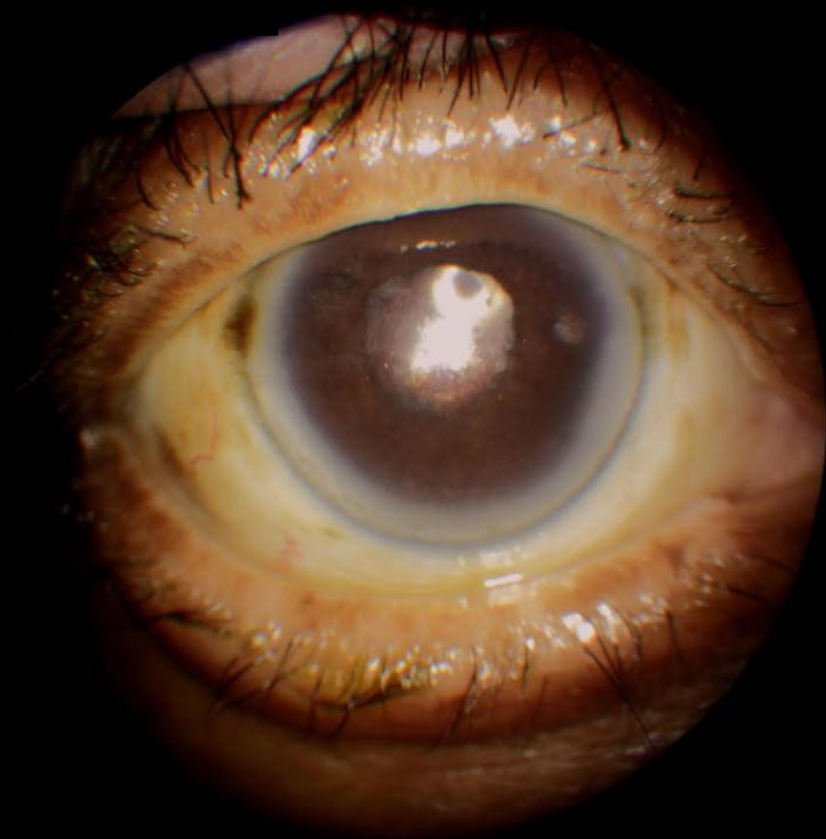
VA OS: CF

IOP OS: 12mmHg

Slit lamp exam OS: Avascular elevated bleb, seidel?, clear cornea, normal depth anterior chamber with no cells, phakic (white cataract)



14d post op



14d post op

