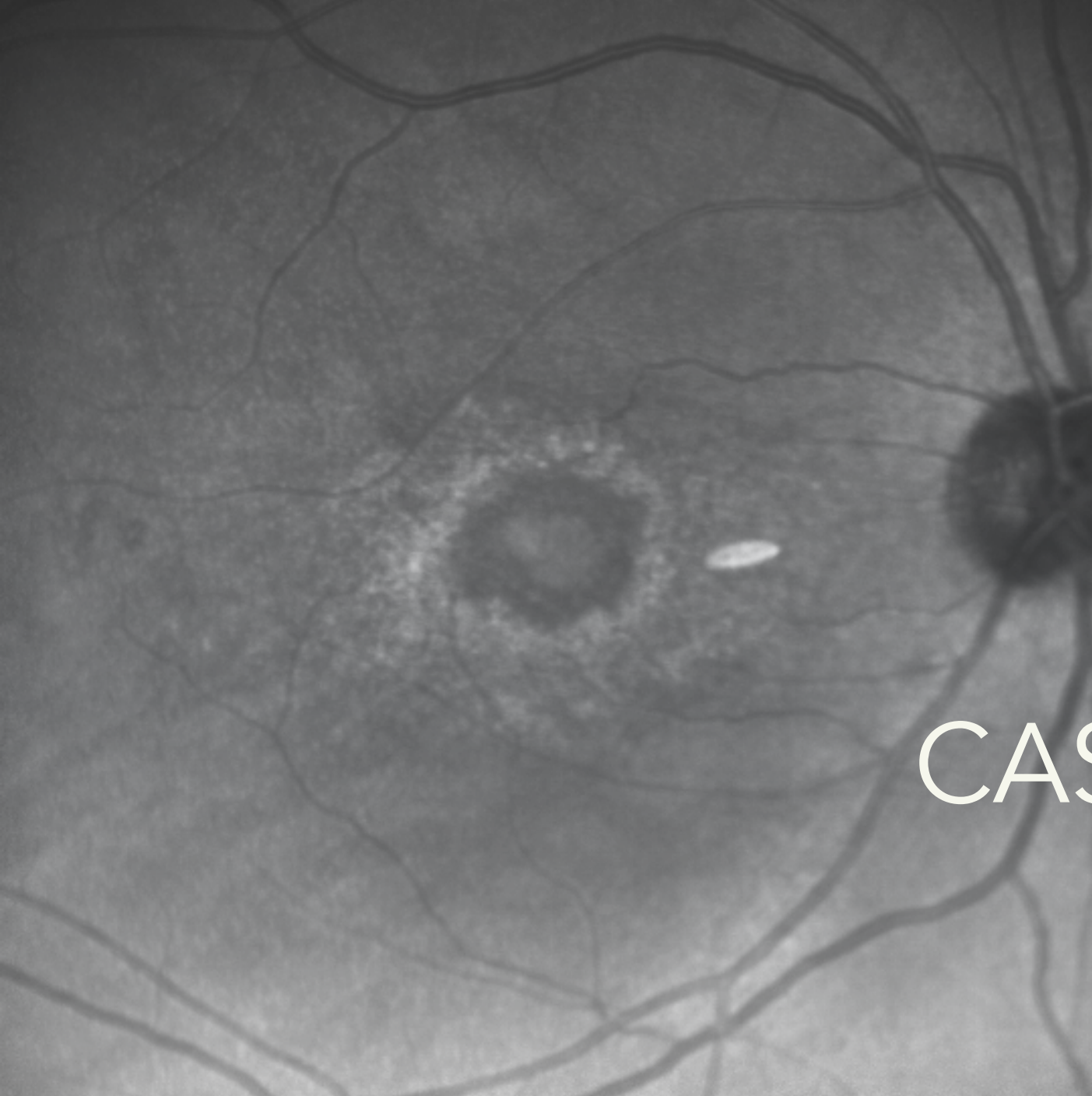

CASO CLÍNICO

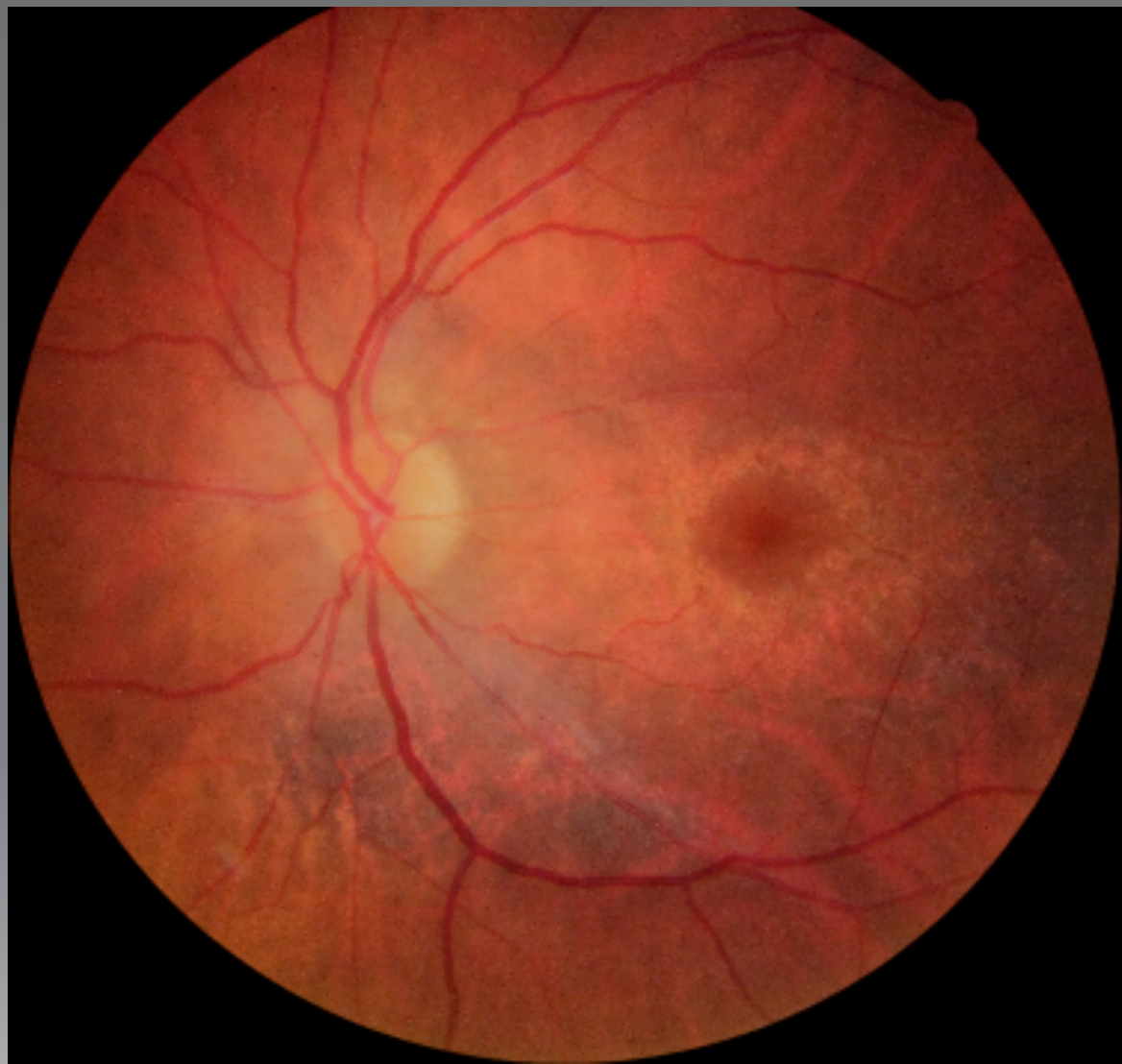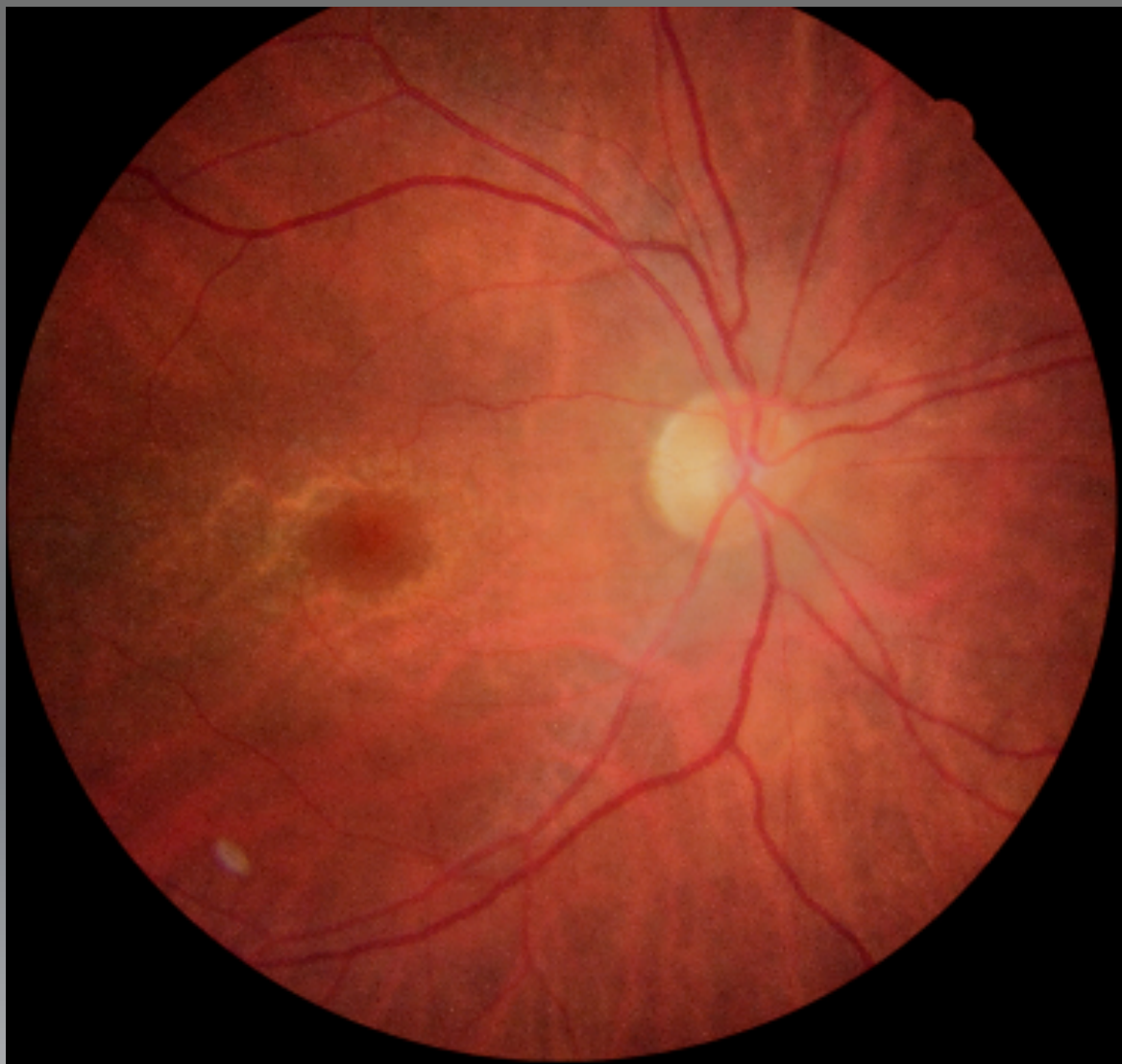E1 THAÍS BASTOS

CASO CLÍNICO

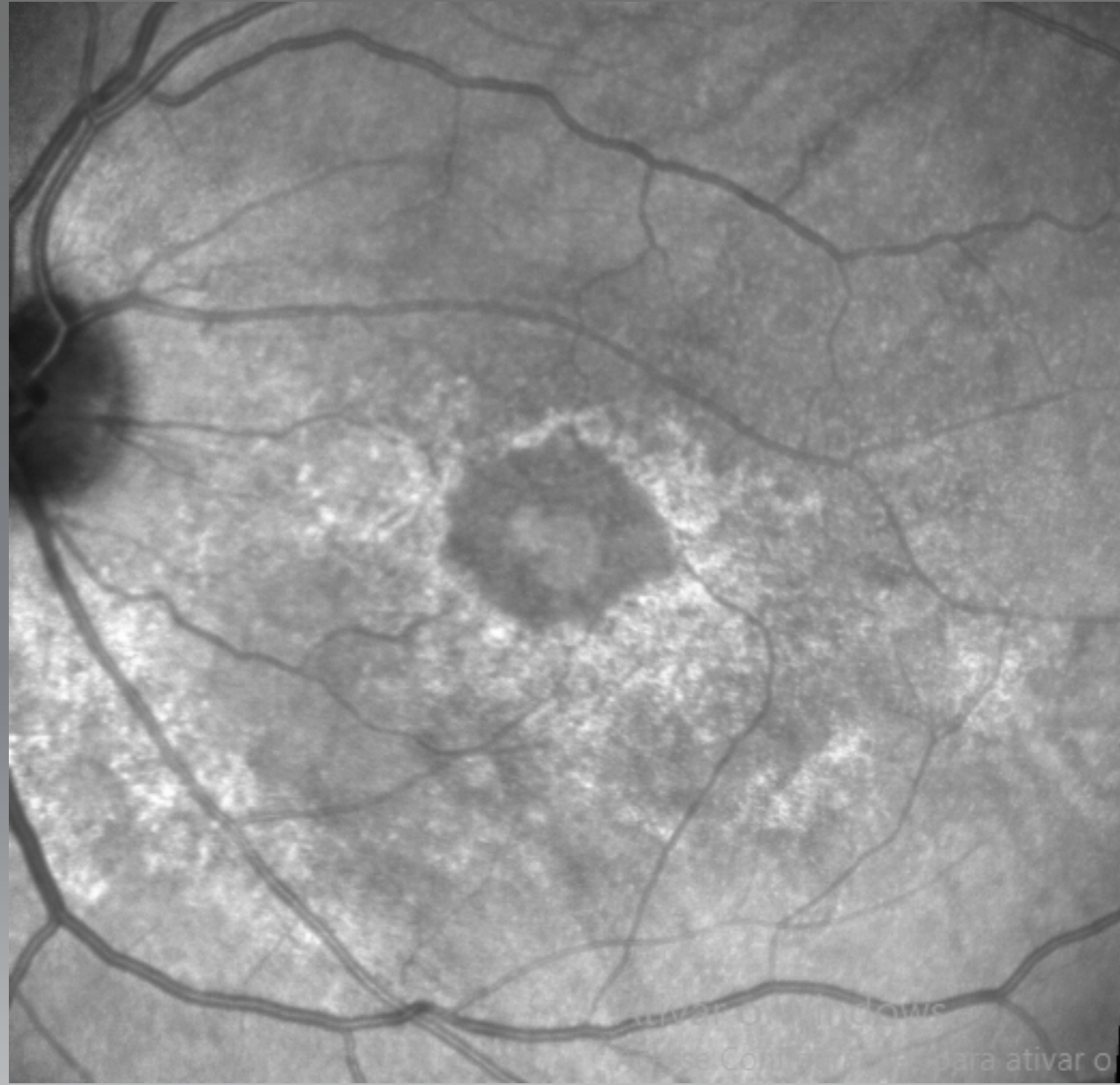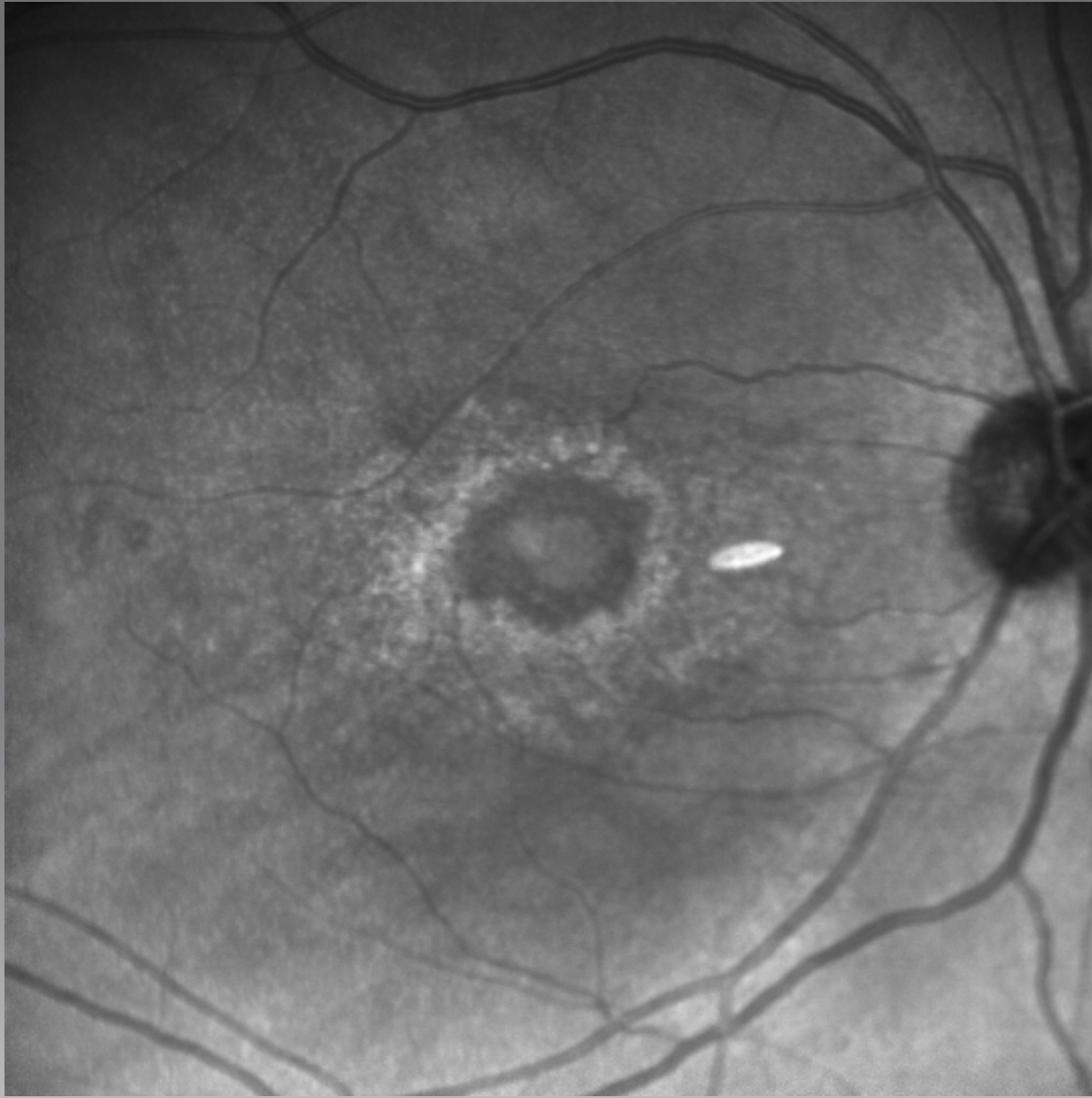
- 57 ANOS, feminino
- Solicitado PI pela reumatologia. Sem queixas oftalmológicas.
- AP: LES

EXAME

- AV: 20/25 AO
- BIO: pseudofácica AO




MÁCULA EM BULL'S EYE



Use Ctrl + Alt + T para ativar o


Monitor de Fixação: **Fixação/Mancha Cega** Estimulo: **III, Branco** Data: **13/03/2020**
 Mira de Fixação: **Central** Fundo: **31,5 asb** Hora: **11:14**
 Perdas de Fixação: **0/15** Estratégia: **SITA Fast** Idade: **56**
 Erros Falsos POS: **1%** Diâmetro de Pupila: **5,4 mm ***
 Erros Falsos NEG: **ND** Acuidade Visual: Refr: **+2,00 DS**
 Duração do Teste: **07:37**
 Fóvea: **35 dB**



-8-27	90-11
-21-34-12-27-32-29	-5-18-3-11-16-10
-04-34-35-05-08-34-04-04	-18-19-19-19-19-19-19
-05-35-35-05-30-35-04	-19-19-20-20-18-20-19-19
-34-35-35-30-17-36-31-35-35-34	-19-19-20-20-1-15-16-20-19-18
-06-36-36-06-14-11-30-36-36-34	-19-20-20-20-2-4-14-20-19-18
-06-35-36-36-36-36-35-05	-19-20-20-20-20-20-20-19
-36-22-16-21-35-33-36-15	-15-7-0-5-26-18-12-1
-25-21-8-12-29-10	-8-5-6-4-14-6
-19-11	-3-4


Desvio Total

Desvio Padrão




MD10-2: **-29,78 dB P < 1%**
 PSD10-2: **8,71 dB P < 1%**

□ P < 5%
 ○ P < 2%
 ● P < 1%




Monitor de Fixação: **Fixação/Mancha Cega** Estimulo: **III, Branco** Data: **13/03/2020**
 Mira de Fixação: **Central** Fundo: **31,5 asb** Hora: **11:24**
 Perdas de Fixação: **0/16** Estratégia: **SITA Fast** Idade: **56**
 Erros Falsos POS: **0%** Diâmetro de Pupila: **4,6 mm ***
 Erros Falsos NEG: **0%** Acuidade Visual: Refr: **+2,00 DS**
 Duração do Teste: **07:25**
 Fóvea: **32 dB**



-33-28	-23-18
-33-34-34-34-34-34	-23-23-23-23-23-23
-04-34-34-05-05-35-04-04	-23-24-24-24-24-24-24
-04-35-35-05-35-35-05	-24-24-25-25-25-25-24
-34-35-35-30-17-18-34-35-35-34	-23-24-25-20-1-7-23-25-25-24
-34-36-36-34-29-11-23-36-36-35	-23-24-25-23-16-9-13-25-26-24
-05-35-36-36-36-36-35-05	-24-25-25-25-25-25-25
-05-35-30-29-21-25-17-8	-24-24-19-19-11-15-6-2
-8-5-5-5-7-5	2-5-6-5-3-6
-8-6	1-5

Desvio Total

Desvio Padrão

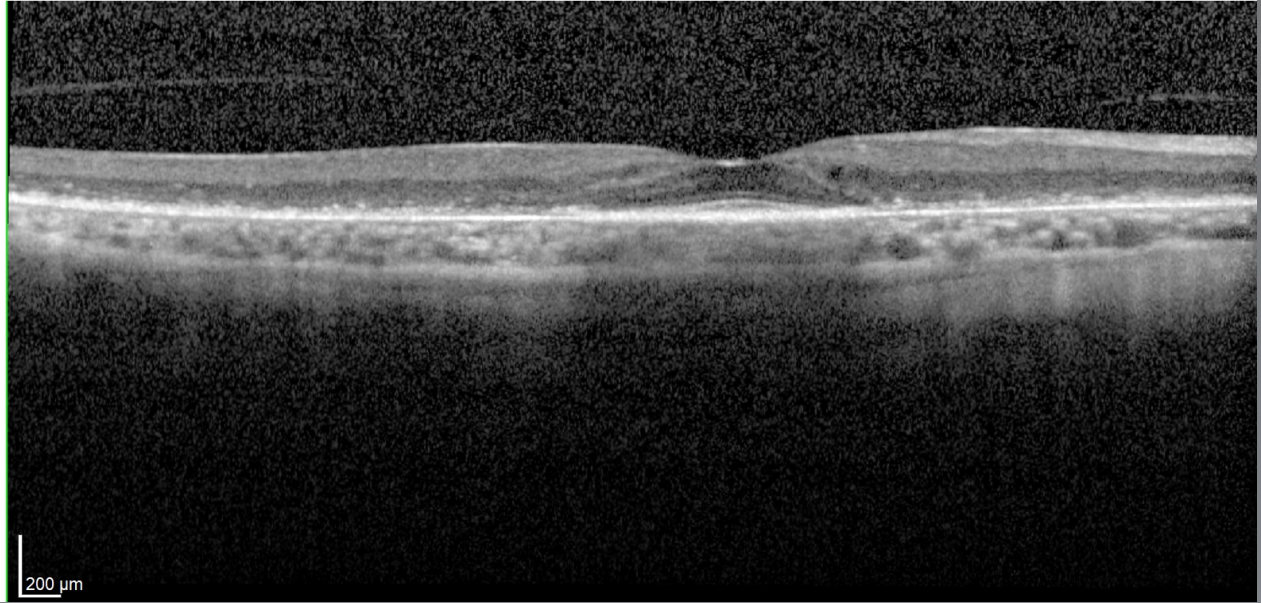
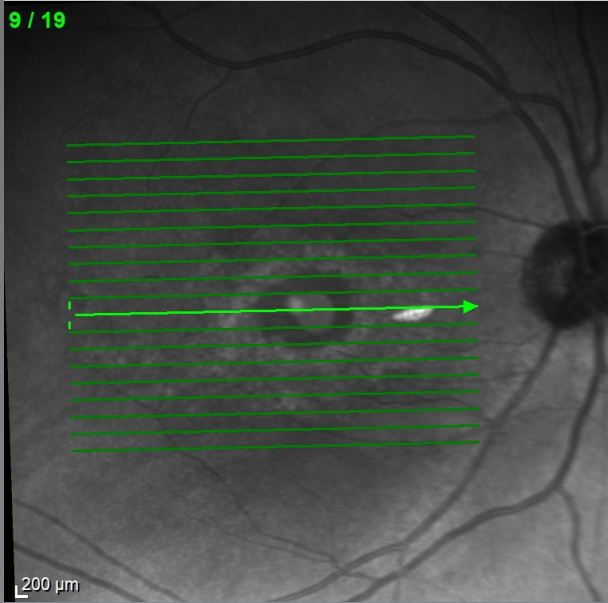


MD10-2: **-29,31 dB P < 1%**
 PSD10-2: **10,38 dB P < 1%**

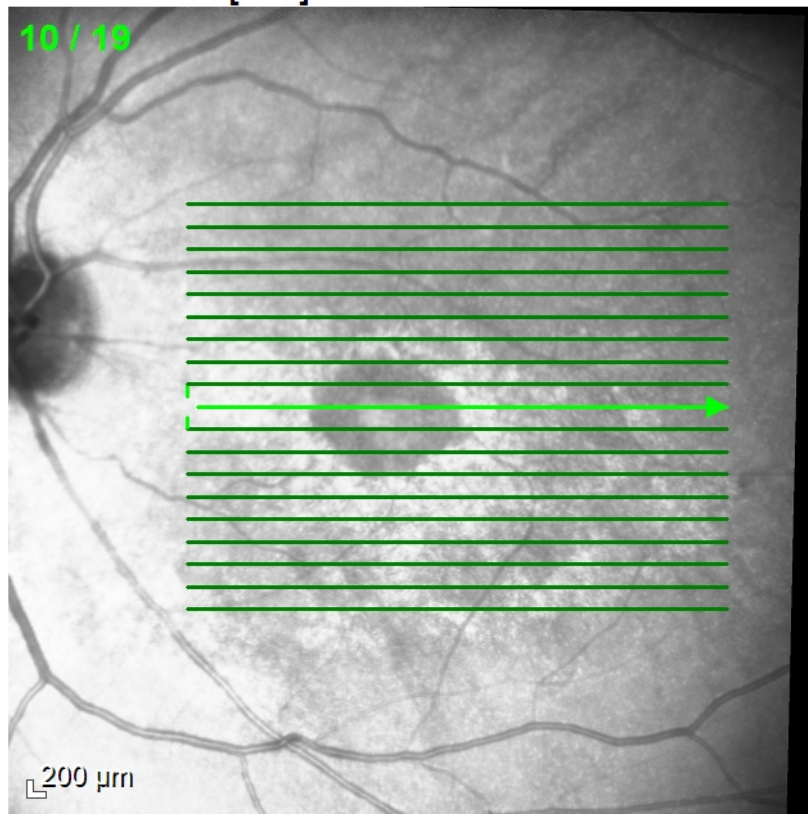
□ P < 5%
 ○ P < 2%
 ● P < 1%



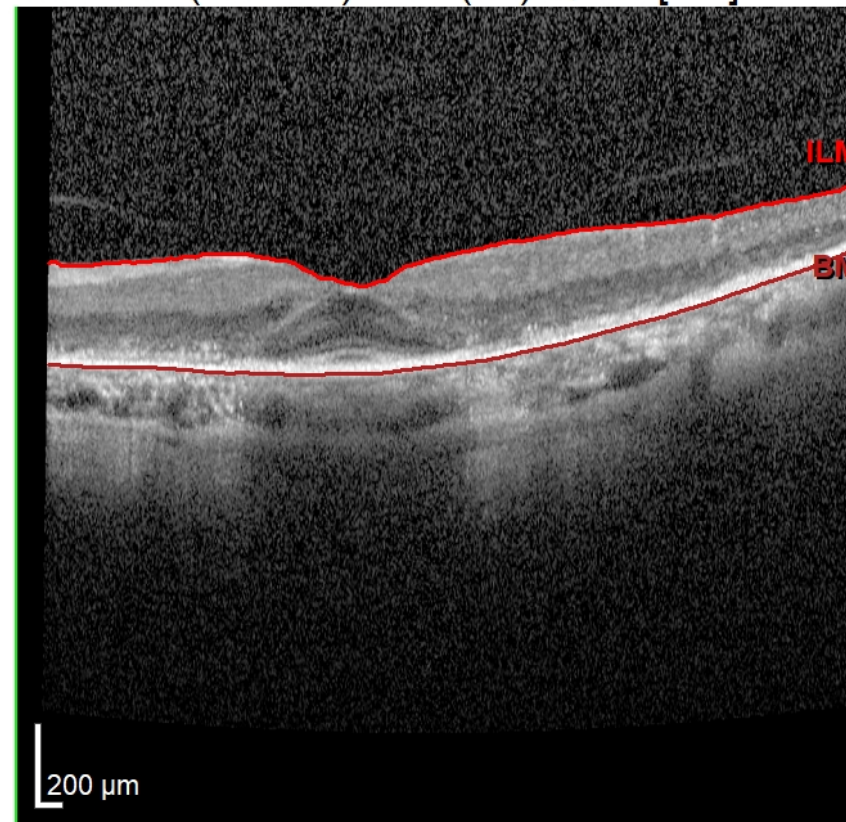
9 / 19



IR 30° ART [HR]



OCT 20° (5.8 mm) ART (24) Q: 22 [HR]

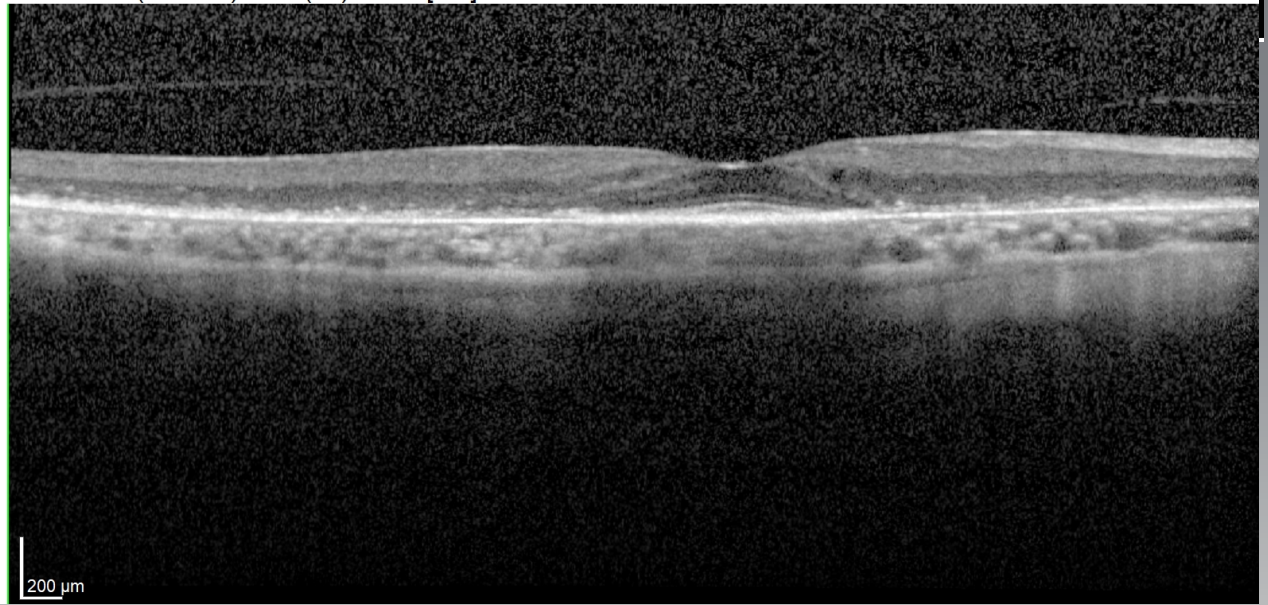
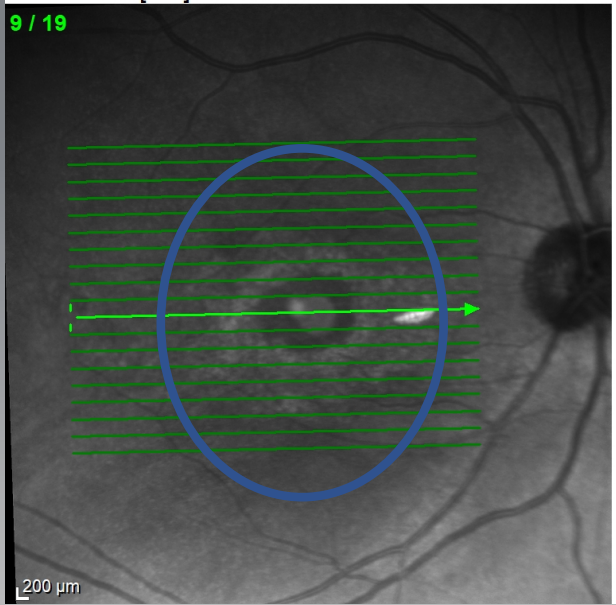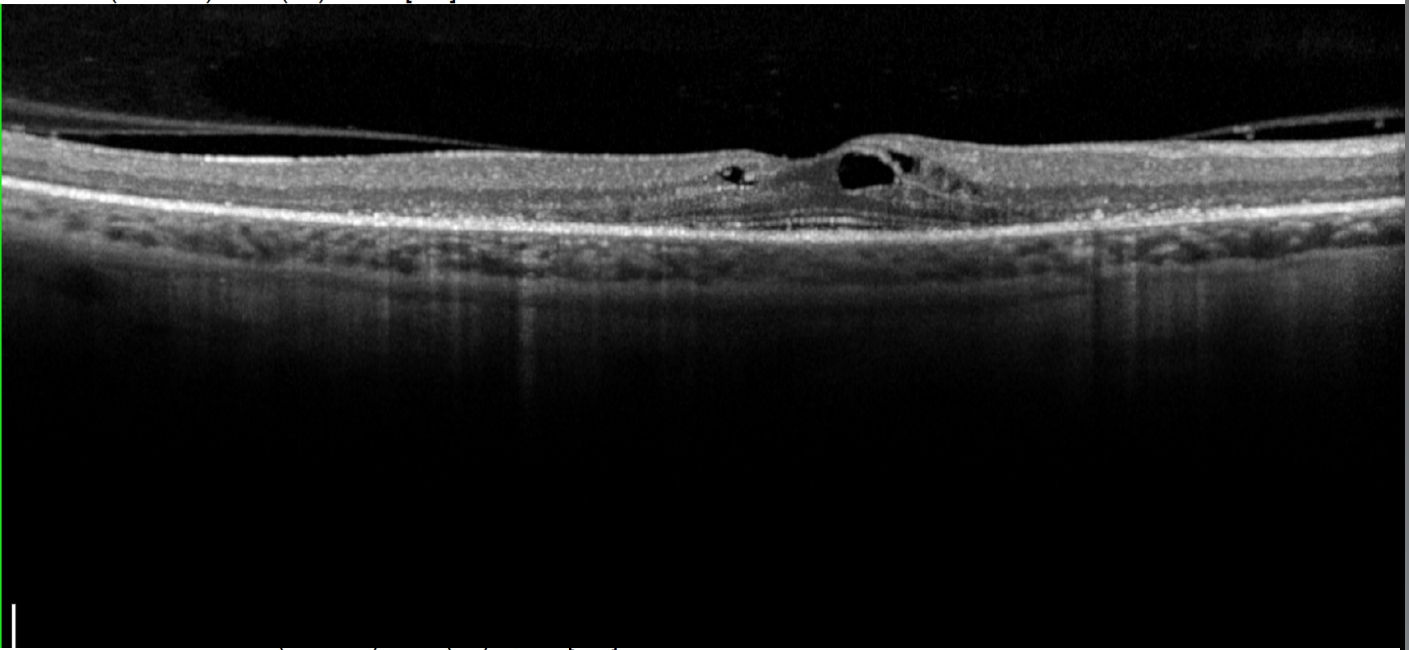
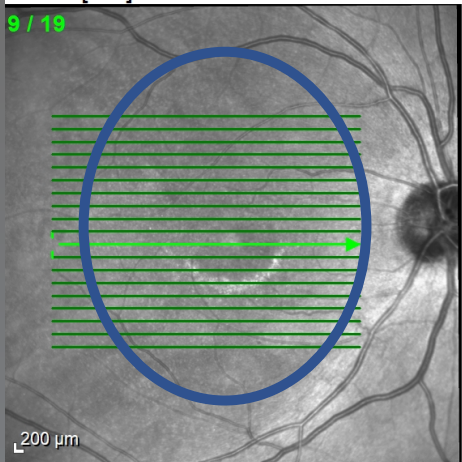


HIPÓTESE DIAGNÓSTICA

- MACULOPATIA POR CLOROQUINA
- DIAGNÓSTICO DIFERENCIAL – MÁCULA EM BULL`S EYE
 - DISTROFIA MACULAR ANULAR CONCÊNTRICA BENIGNA
 - DISTROFIA DE CONES
 - ACROMATOPSIA
 - DISTROFIA DE CONES E BASTONETES

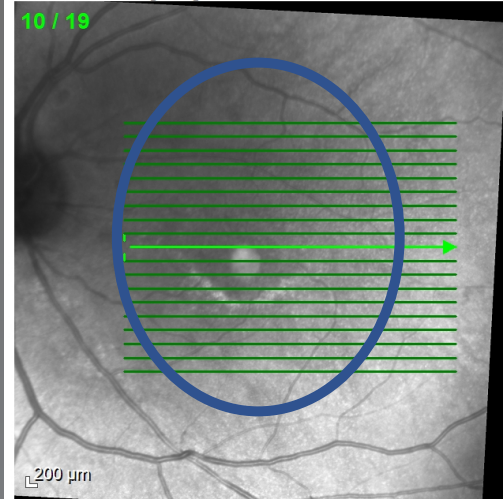
2014

- DIAGNÓSTICO DE MACULOPATIA POR CLOROQUINA
- JÁ HAVIA SIDO SUSPENSA MEDICAÇÃO
- MEDICAÇÃO DE DEPÓSITO – EVOLUÇÃO DA MACULOPATIA MESMO APÓS SUSPENSÃO DA DROGA

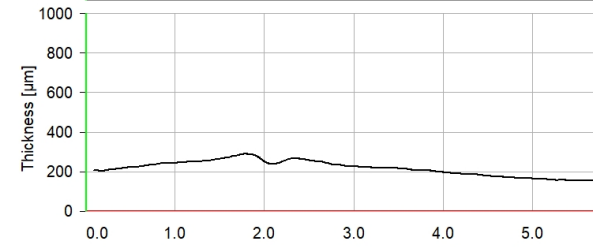
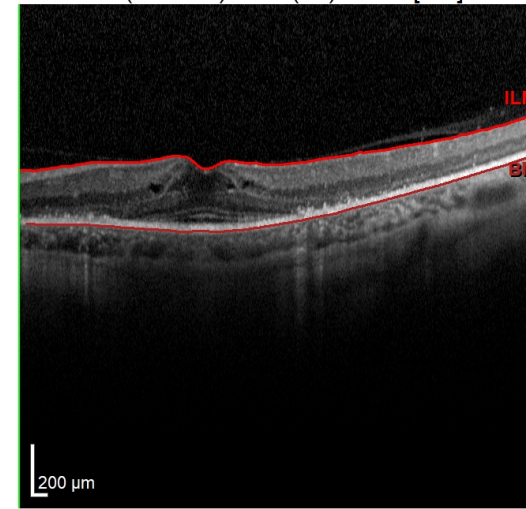


Reference 14/out/2014

IR 30° ART [HR]

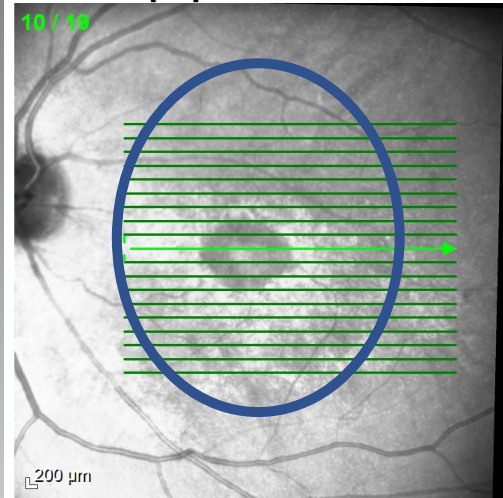


OCT 20° (5.8 mm) ART (24) Q: 18 [HR]

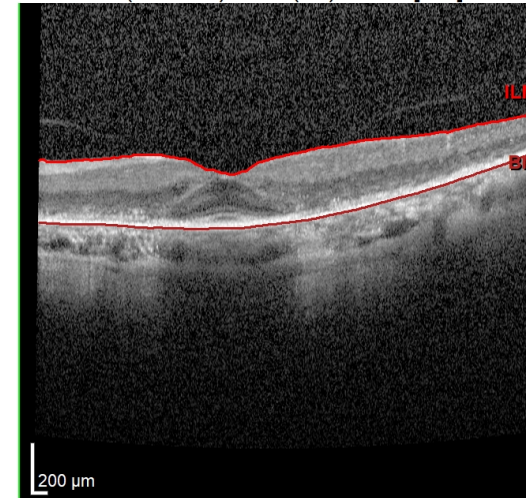


Follow-Up #6 13/mar/2020

IR 30° ART [HR]



OCT 20° (5.8 mm) ART (24) Q: 22 [HR]



OBRIGADA!