

# Caso Clínico

Igor Coêlho

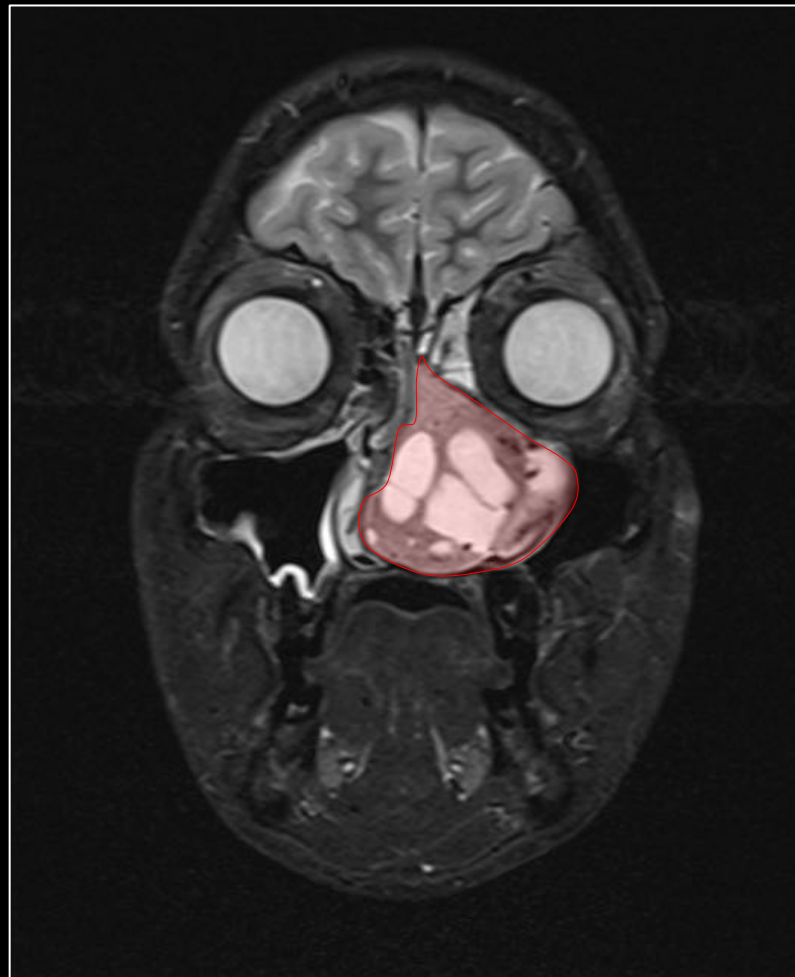Professor Rodrigo Jorge



# Caso Clínico

- Homem , 18 anos de Idade
- HMA: obstrução nasal e epistaxe à esquerda
- Antecedentes Oculares:
  - Nega
- Antecedentes Pessoais:
  - Nega
- Antecedentes Familiares:
  - Nega

RESSONÂNCIA MAGNÉTICA

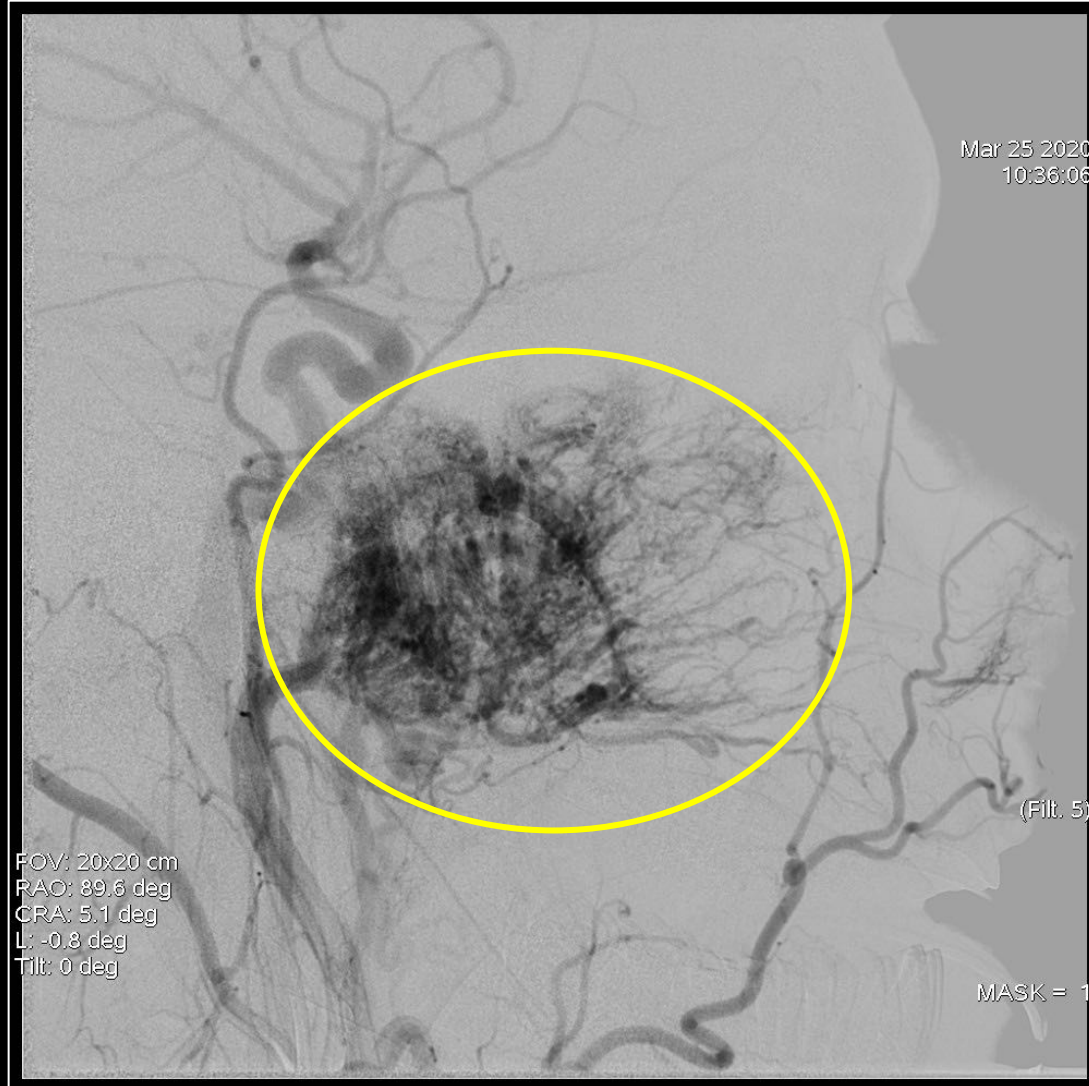


Lesão vascularizada à esquerda. 9 x 5 x 3,9 cm

# Caso Clínico

- Hipótese Diagnóstica :
  - Nasioangiofibroma
- Conduta :
  - Ressecção endoscópica
  - Embolização tumoral antes do procedimento cirúrgico

# ARTERIOGRAFIA

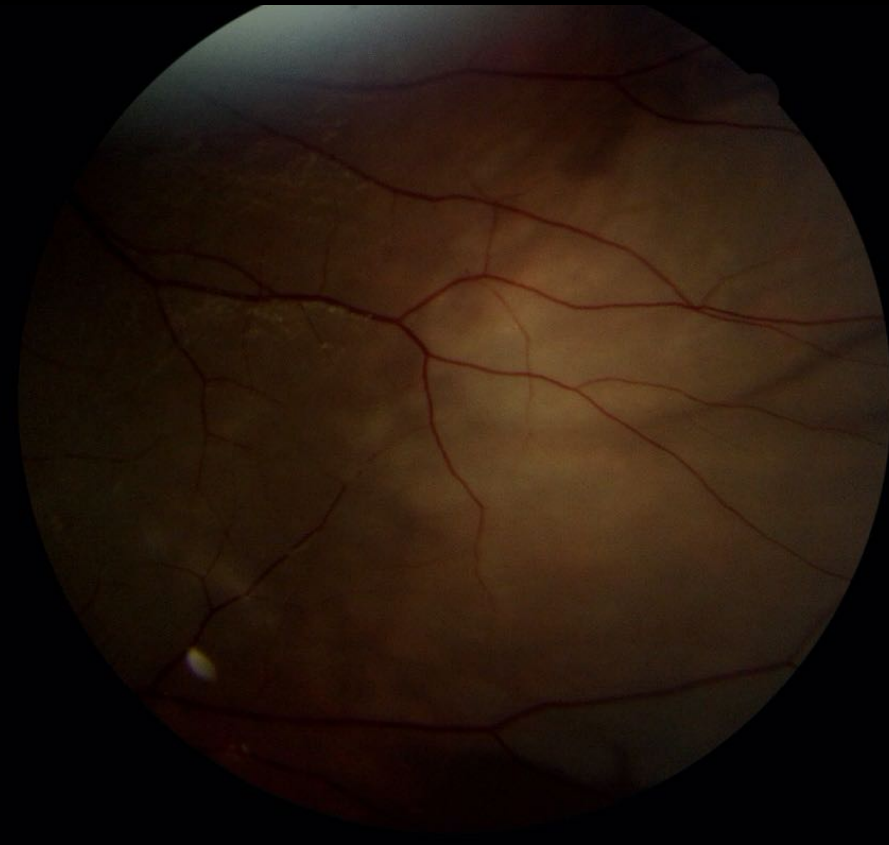
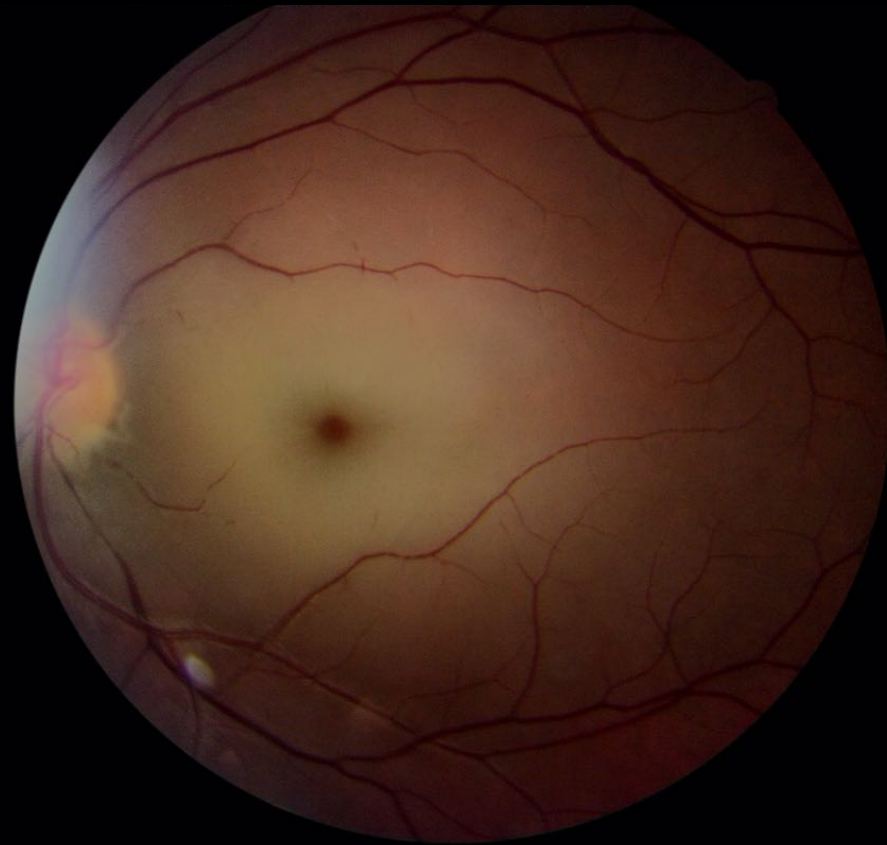
# Caso Clínico

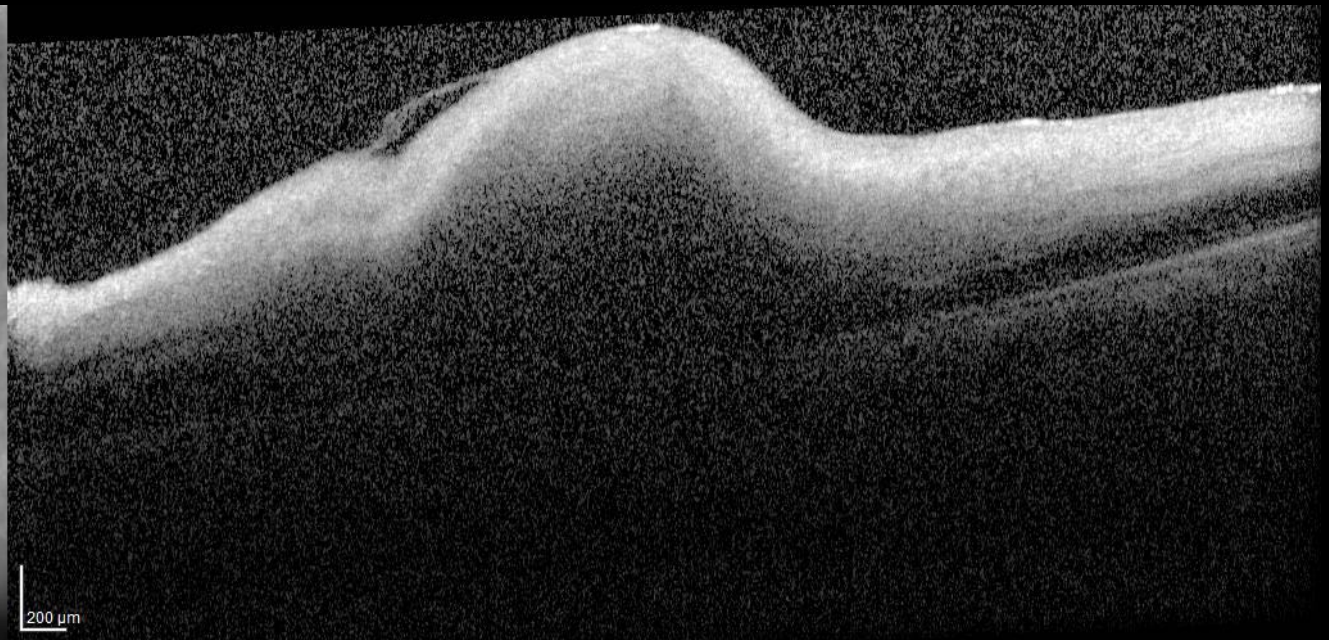
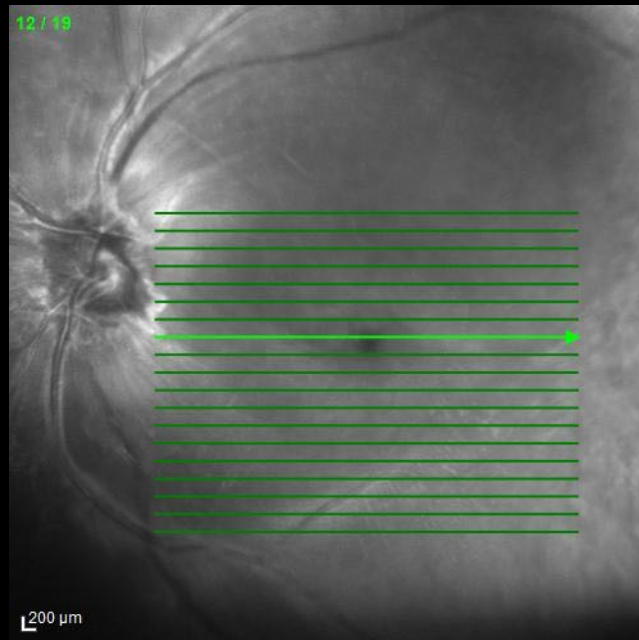
Pós-operatório imediato : Amaurose súbita olho esquerdo

	OD	OE
Acuidade Visual	20/32	PL
Reflexos pupilares		Defeito pupilar aferente
Tonometry	10 mmHg	10mmHg
Biomicroscopia	Fácico	Fácico
Mapeamento de Retina	NOC, esc fisiológica, mácula sem alterações.	...

RETINOGRAFIA



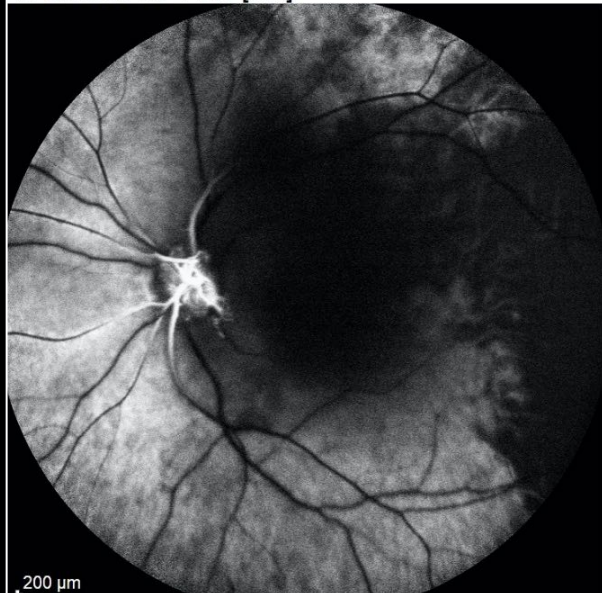
OCT



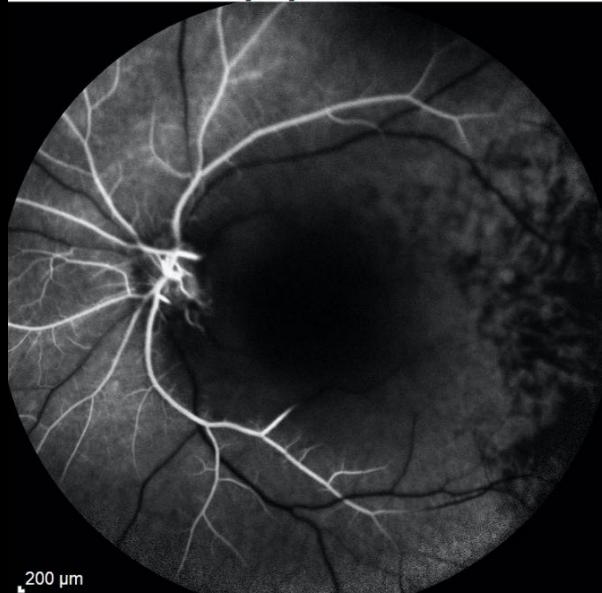


ANGIOGRAFIA FLUORESCÉINICA

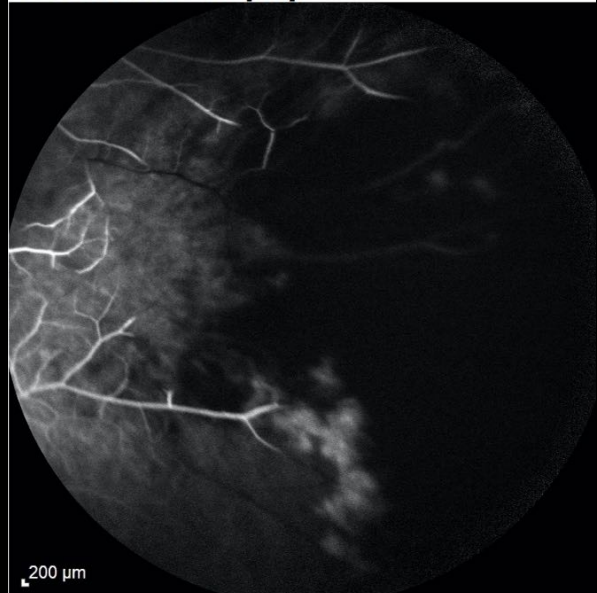
FA 0:25.59 55° ART [HR]



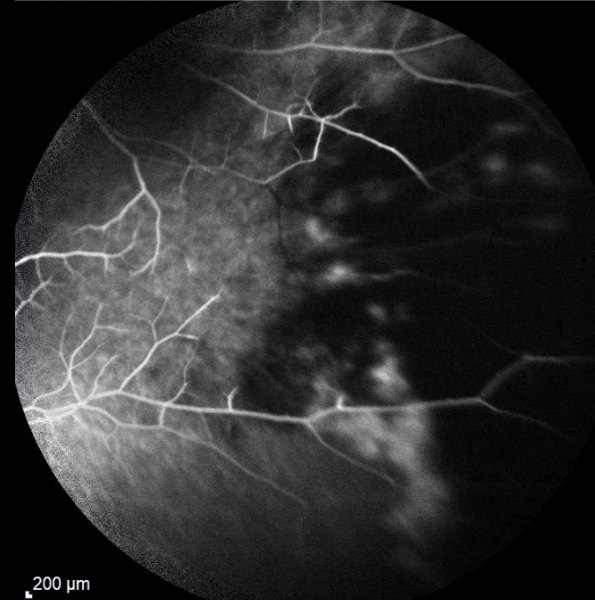
FA 0:52.13 55° ART [HR]



FA 3:28.14 55° ART [HR]



FA 6:00.34 55° ART [HR]



# Caso Clínico

- Hipótese Diagnóstica :
  - Nasioangiofibroma
  - OACR pós embolização

# Caso Clínico

## Journal Pre-proof

Iatrogenic Ophthalmic Artery Occlusion and Retinal Artery Occlusion

Jong Suk Lee, Jun Yup Kim, Cheolkyu Jung, Se Joon Woo

PII: S1350-9462(20)30020-3

DOI: <https://doi.org/10.1016/j.preteyeres.2020.100848>

Reference: JPRR 100848

To appear in: *Progress in Retinal and Eye Research*

Received Date: 27 November 2019

Revised Date: 3 March 2020

Accepted Date: 4 March 2020

Please cite this article as: Lee, J.S., Kim, J.Y., Jung, C., Woo, S.J., Iatrogenic Ophthalmic Artery Occlusion and Retinal Artery Occlusion, *Progress in Retinal and Eye Research*, <https://doi.org/10.1016/j.preteyeres.2020.100848>.

This is a PDF file of an article that has undergone enhancements after acceptance, such as the addition of a cover page and metadata, and formatting for readability, but it is not yet the definitive version of record. This version will undergo additional copyediting, typesetting and review before it is published in its final form, but we are providing this version to give early visibility of the article. Please note that, during the production process, errors may be discovered which could affect the content, and all legal disclaimers that apply to the journal pertain.

© 2020 Elsevier Ltd. All rights reserved.



Obrigado