

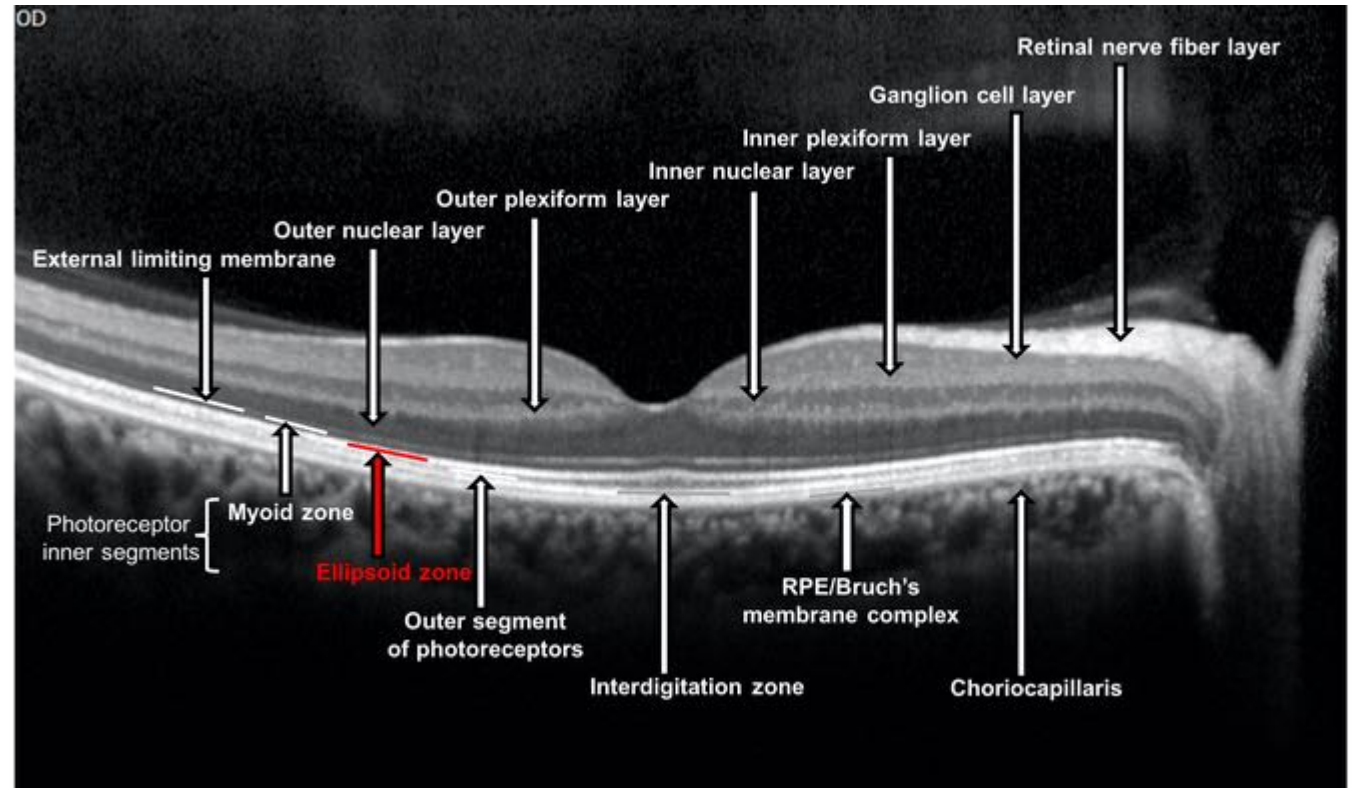

Caso Clínico

Igor Coêlho

Professor Rodrigo Jorge



VÍTREO



ESCLERA

Caso Clínico

- Mulher , 58 anos de Idade
- QP : BAV OD há 1 semana
- Antecedentes Oculares:
 - Nega
- Antecedentes Pessoais:
 - Polimiosite *
 - Uso crônico de Prednisona VO
- Antecedentes Familiares:
 - Nega

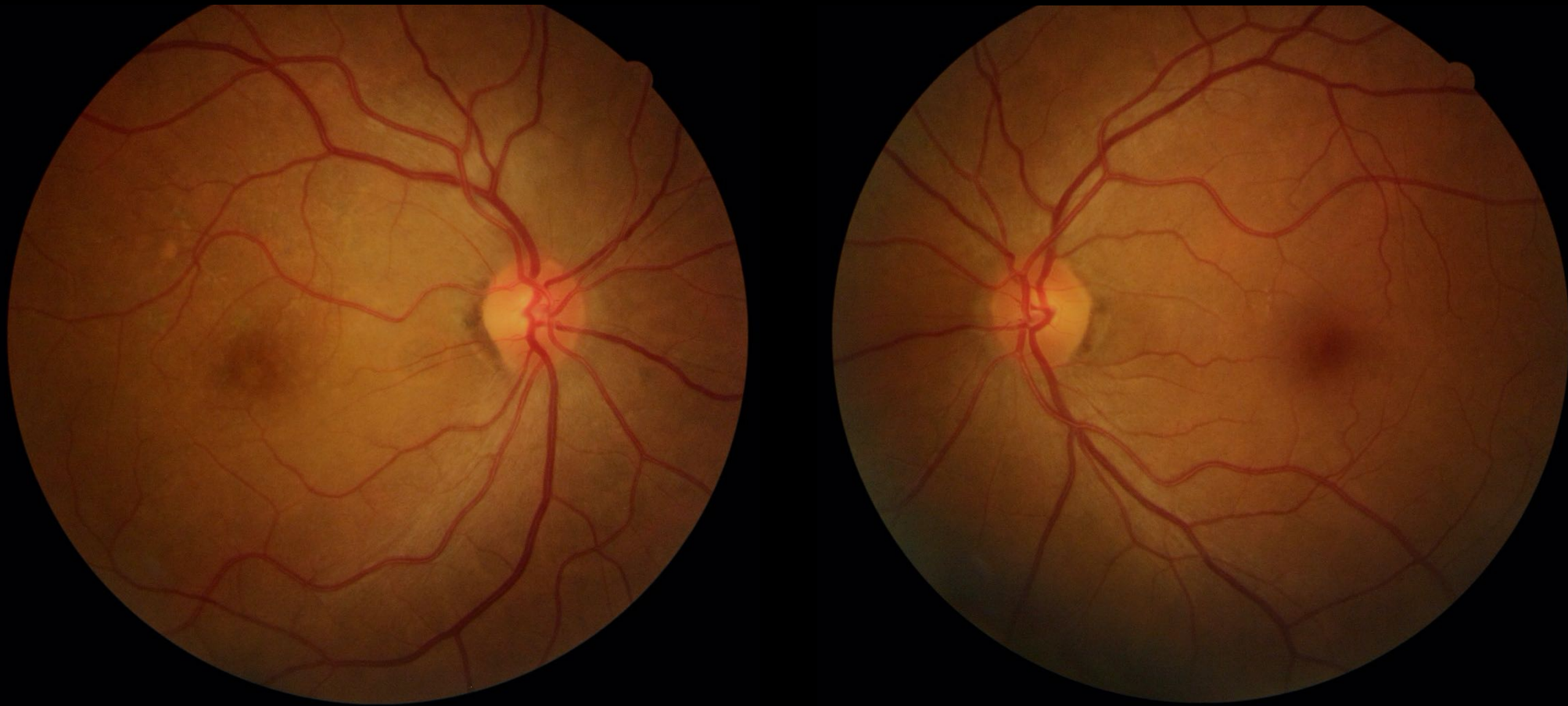
Caso Clínico

- Mulher , 58 anos de Idade
- QP : BAV OD há 1 semana
- Antecedentes Oculares:
 - Nega
- Antecedentes Pessoais:
 - Polimiosite *
 - **Uso crônico de Prednisona VO**
- Antecedentes Familiares:
 - Nega

Caso Clínico

	OD	OE
Acuidade Visual	20/100	20/25
Reflexos pupilares	+	+
Biomicroscopia	Fácico	Fácico
Mapeamento de Retina	...	NOC, esc fisiológica, mácula sem alterações.

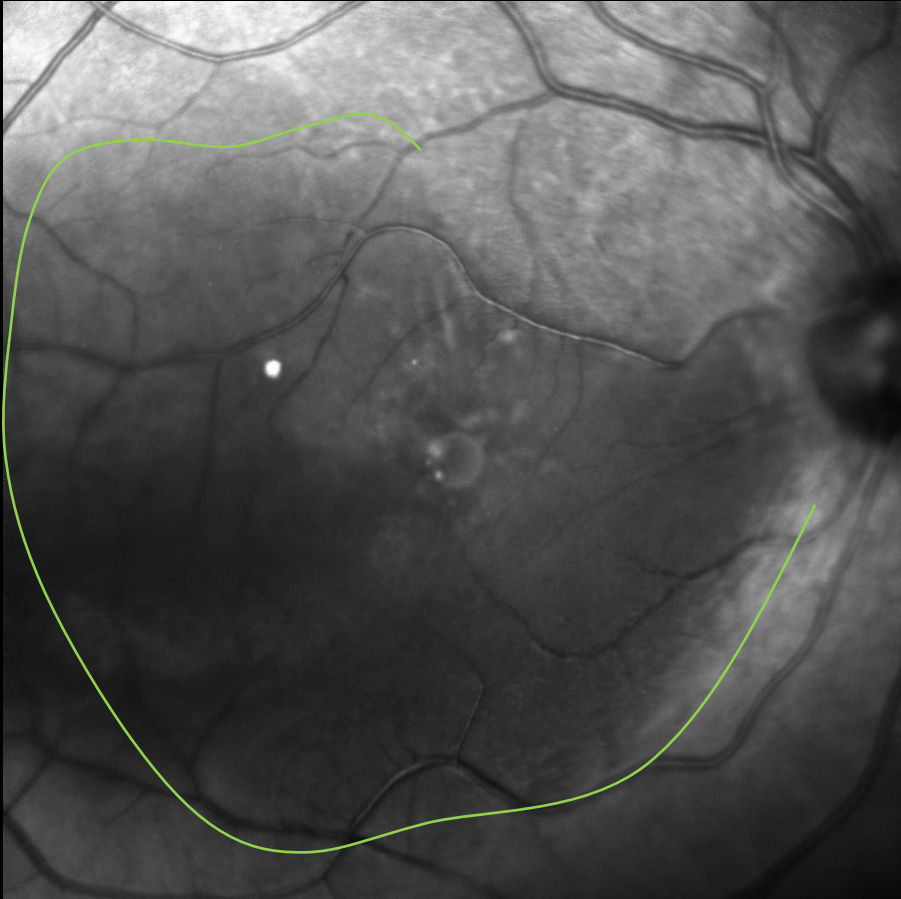
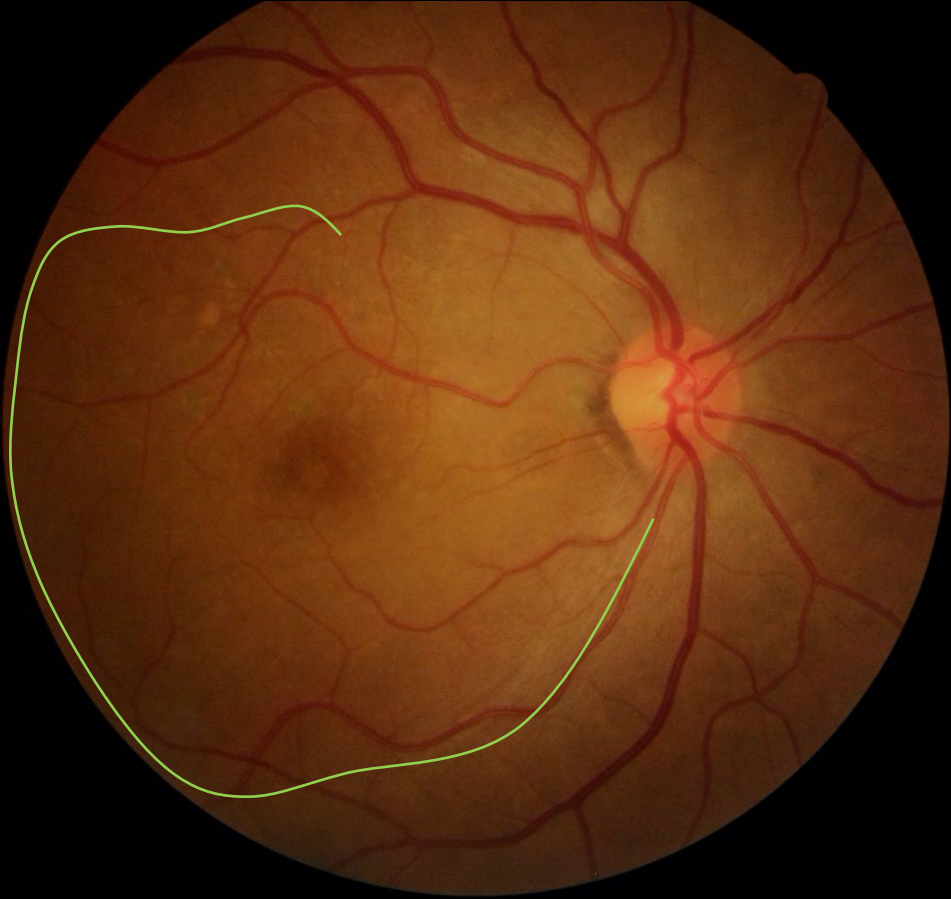
FUNDO DE OLHO



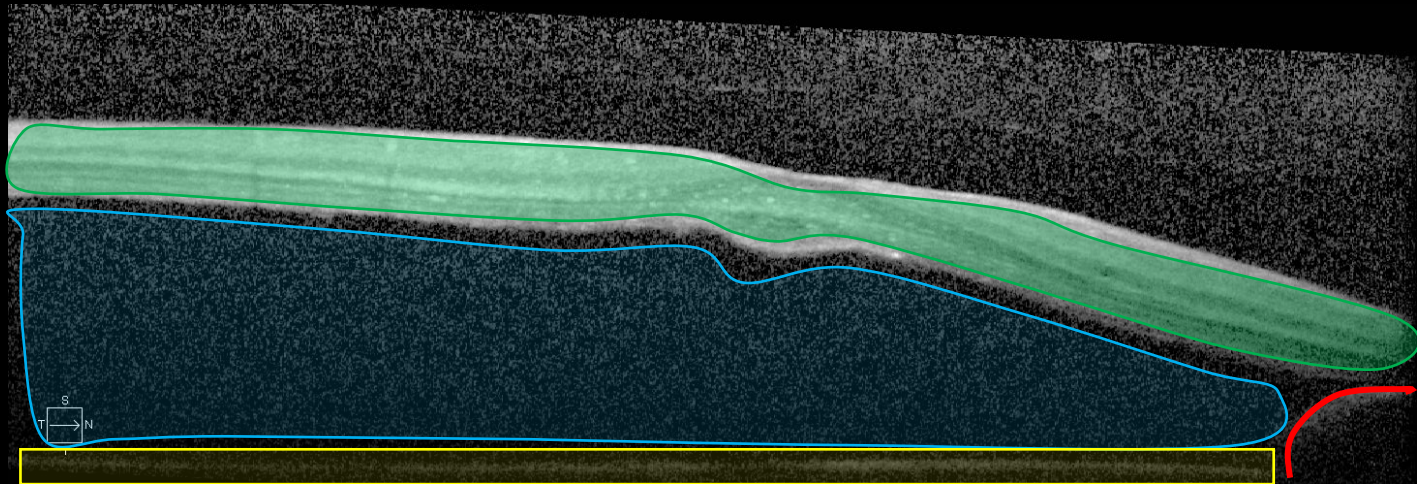
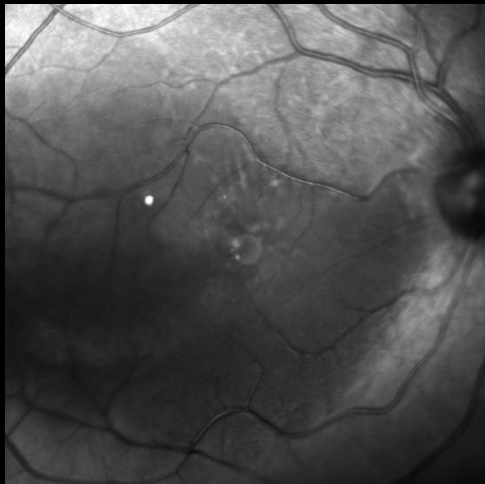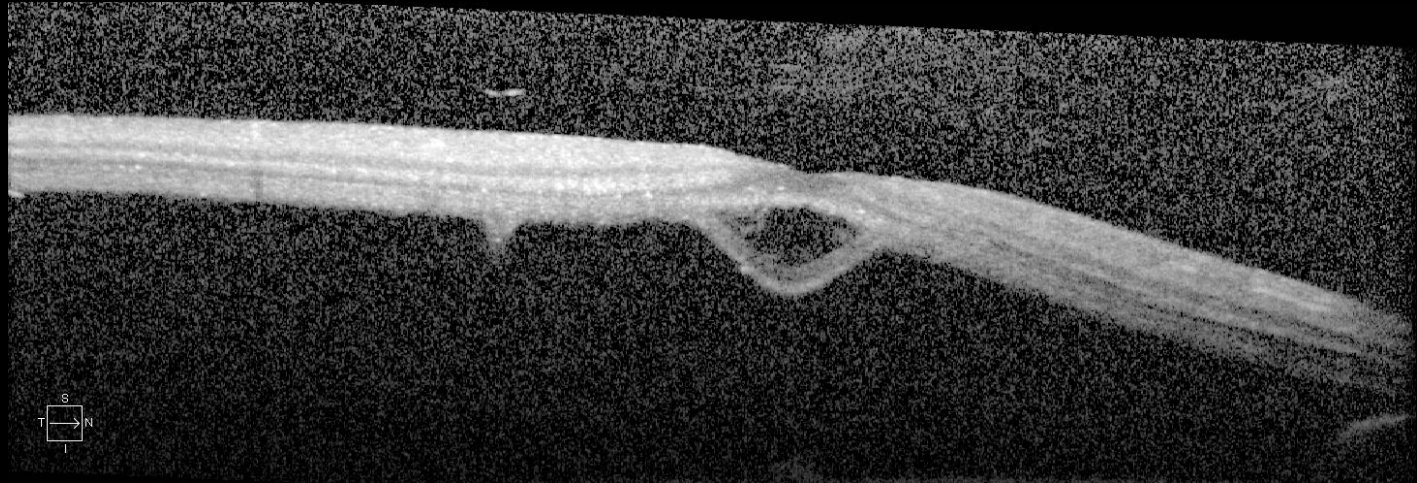
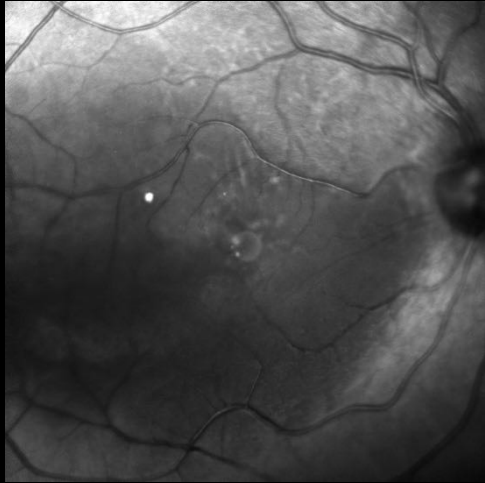FUNDO DE OLHO

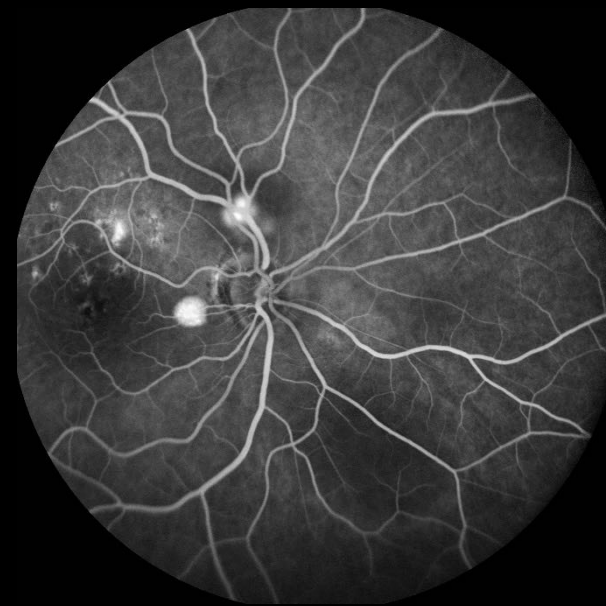
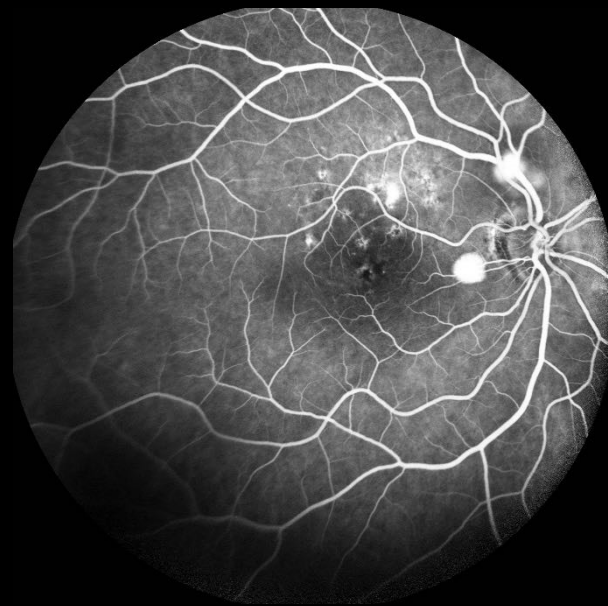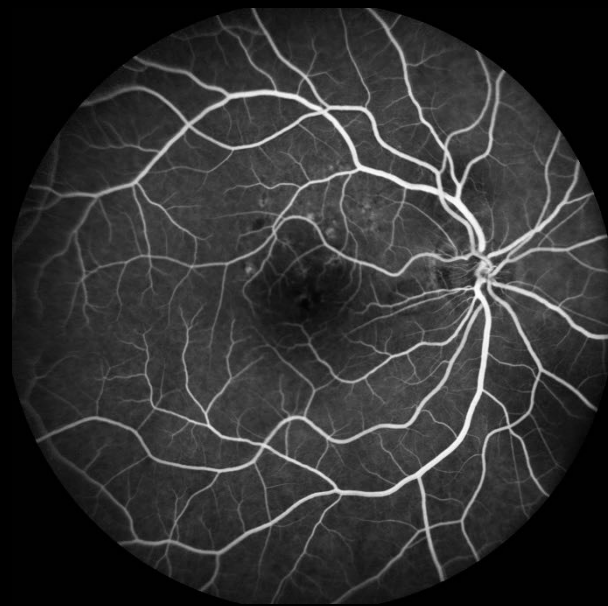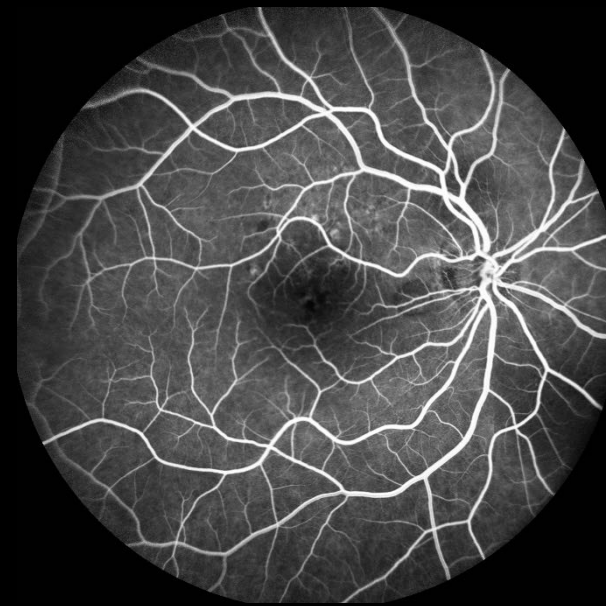
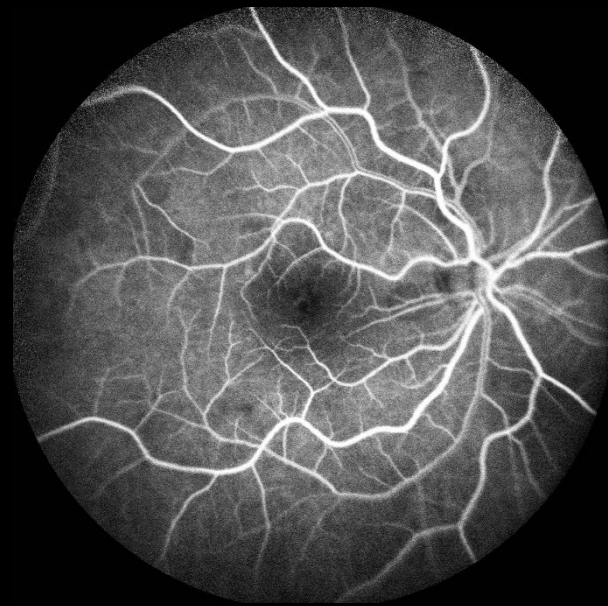
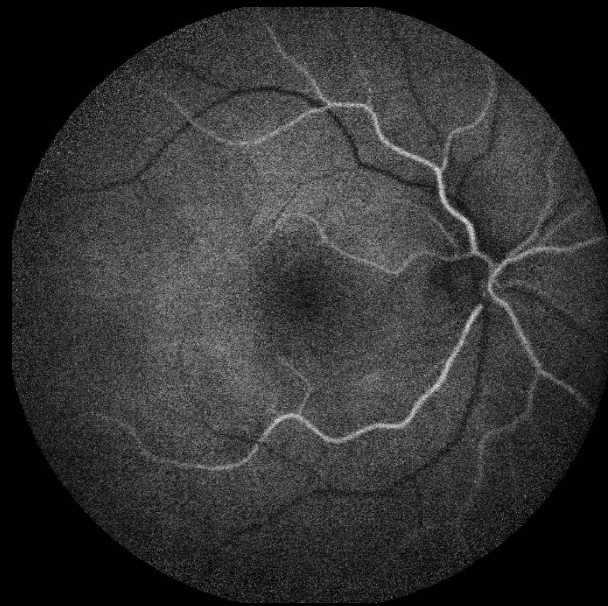
RETINOGRAFIA

IR



OCT

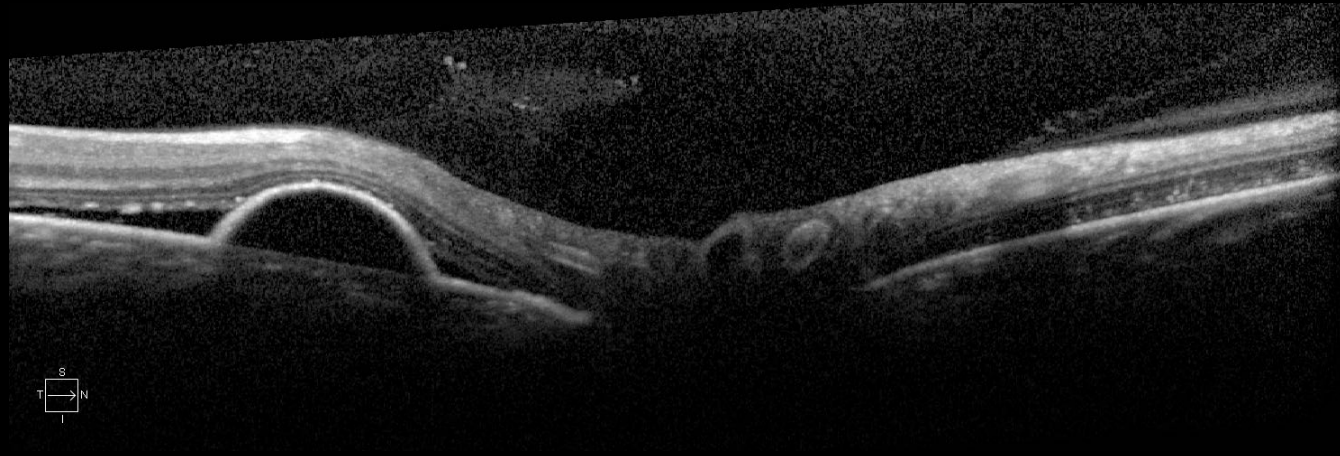
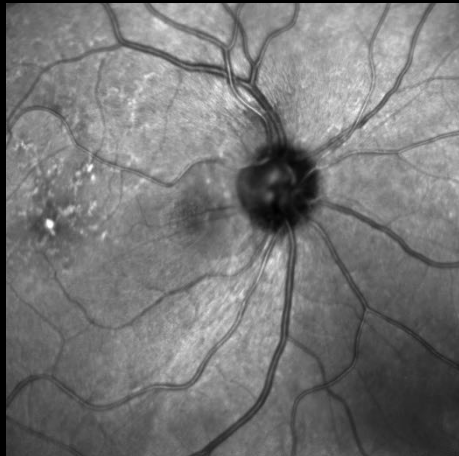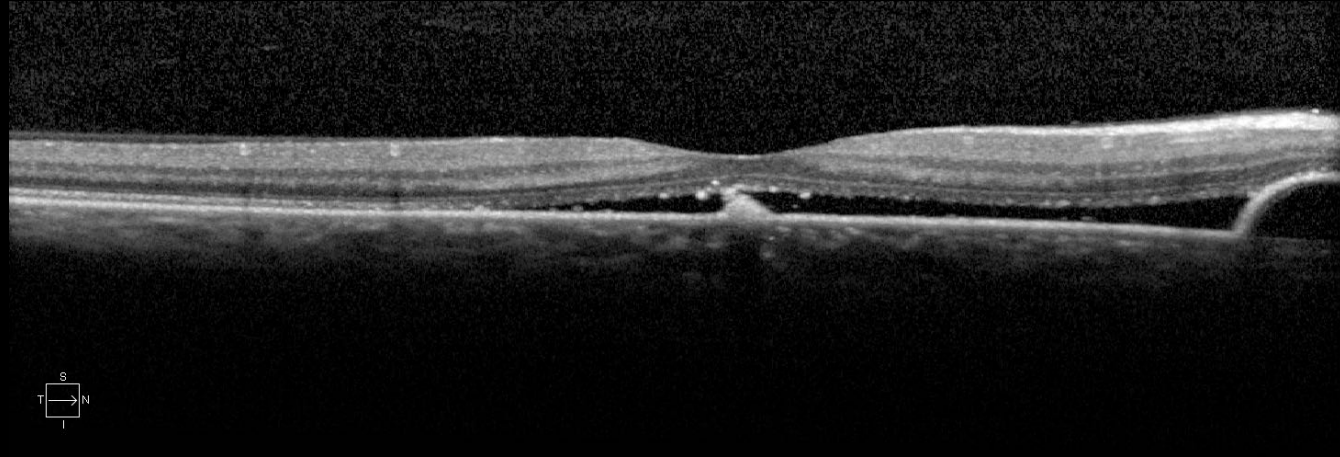

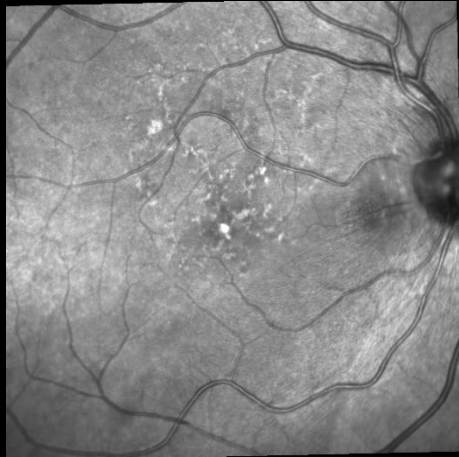


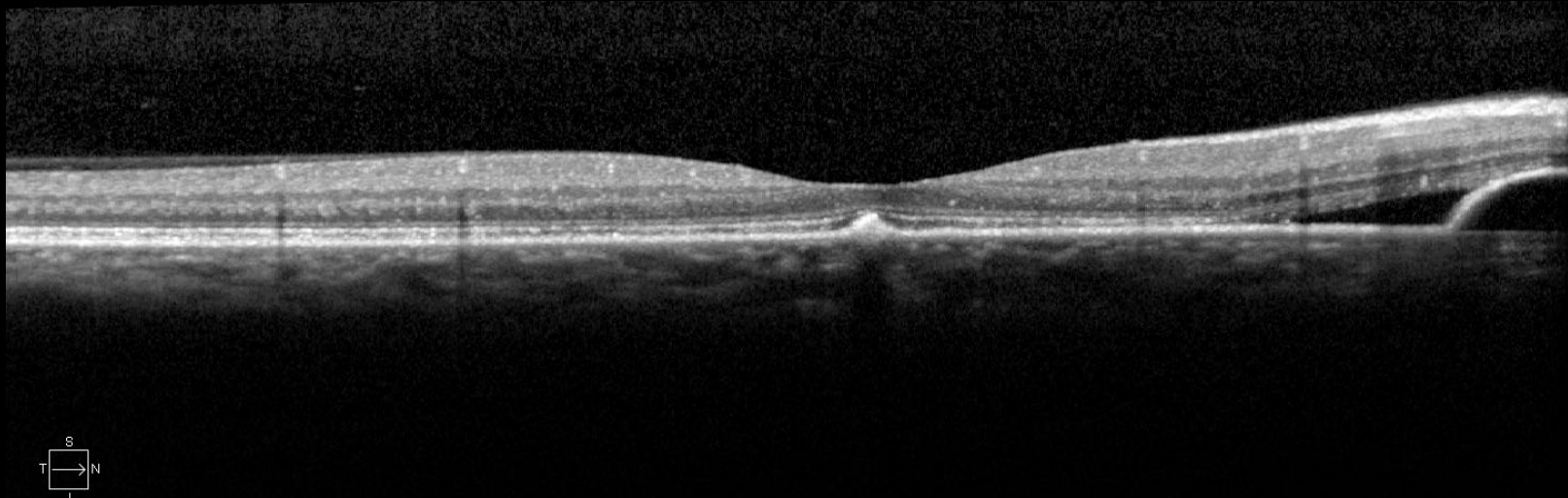
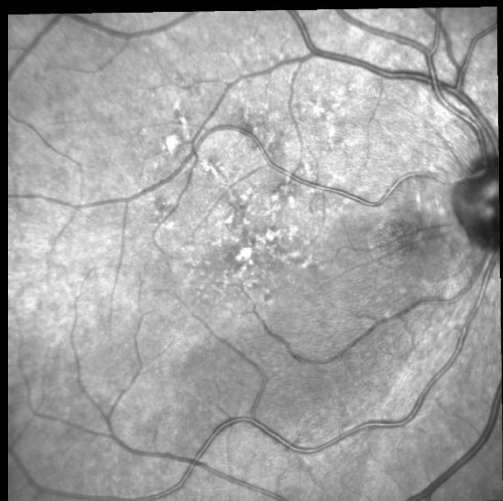
Caso Clínico

- Hipótese Diagnóstica :
 - CSC
- Conduta :
 - Avaliar uso da Pred- Orientado diminuir a dose
 - Espironolactona 50 mg/dia

OCT – 1 MÊS APÓS

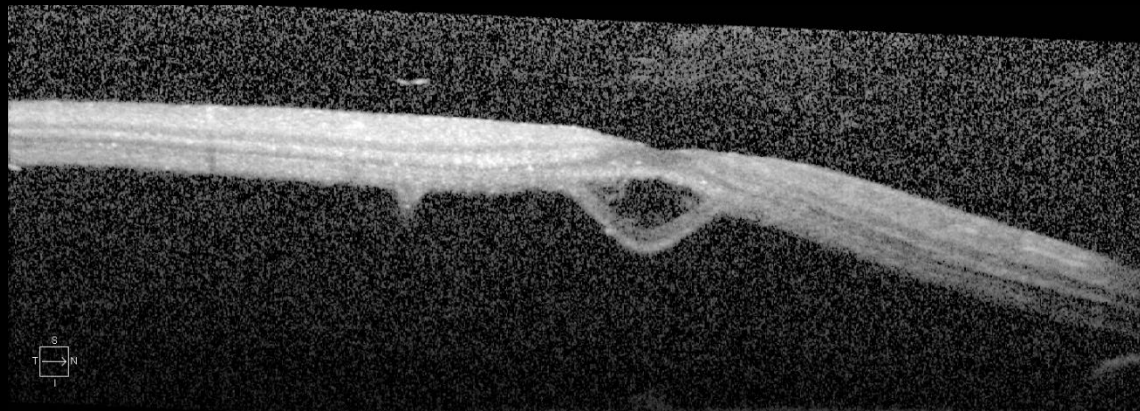
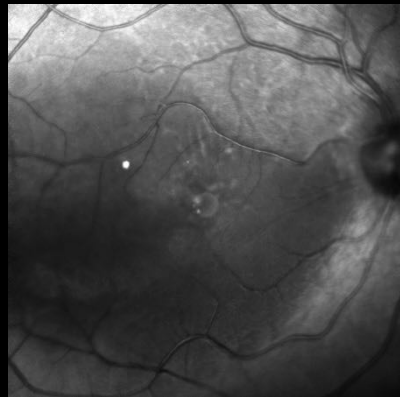


OCT- 6 MESES APÓS

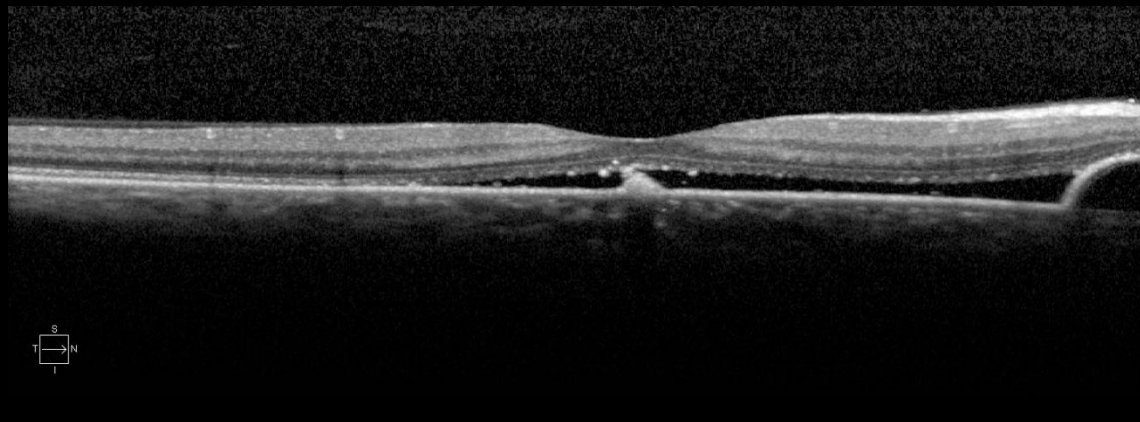
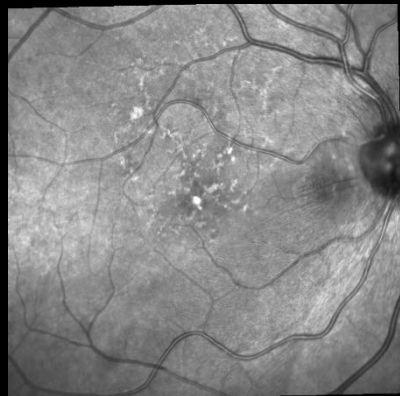

OCT

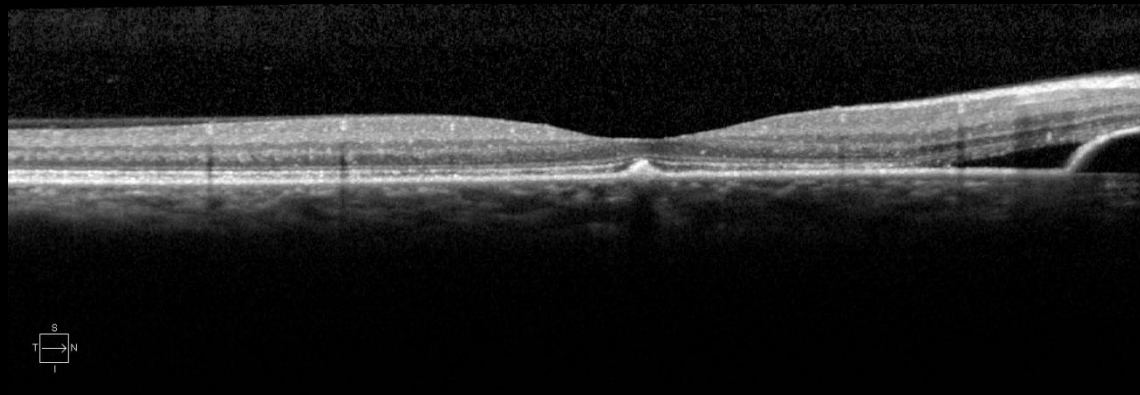
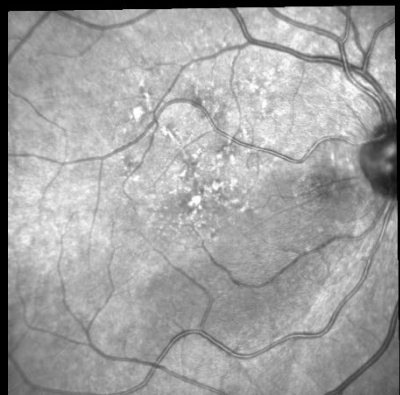
CN



1M



6M



Obrigado