



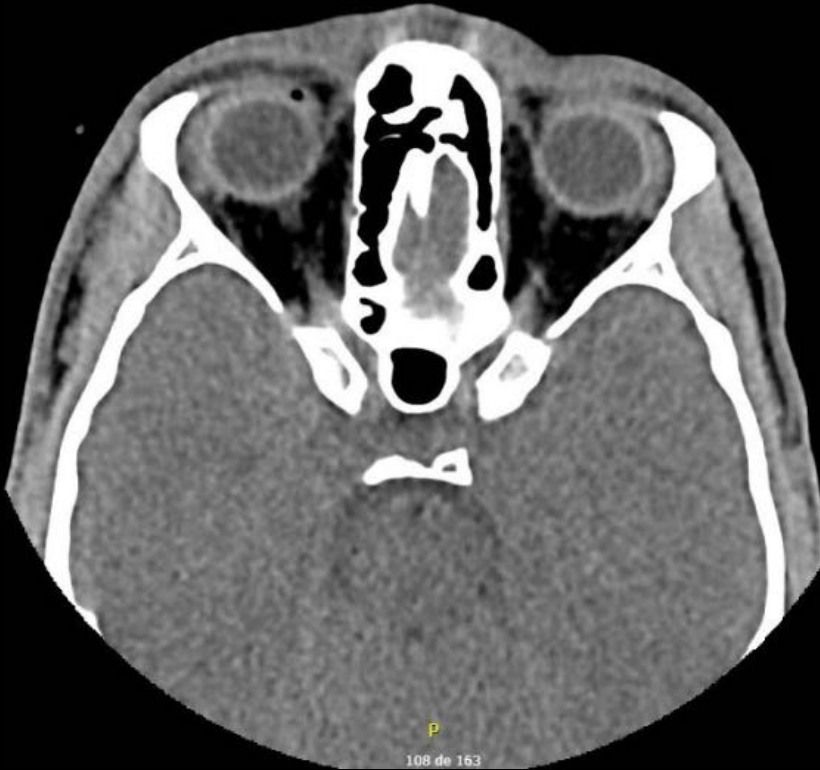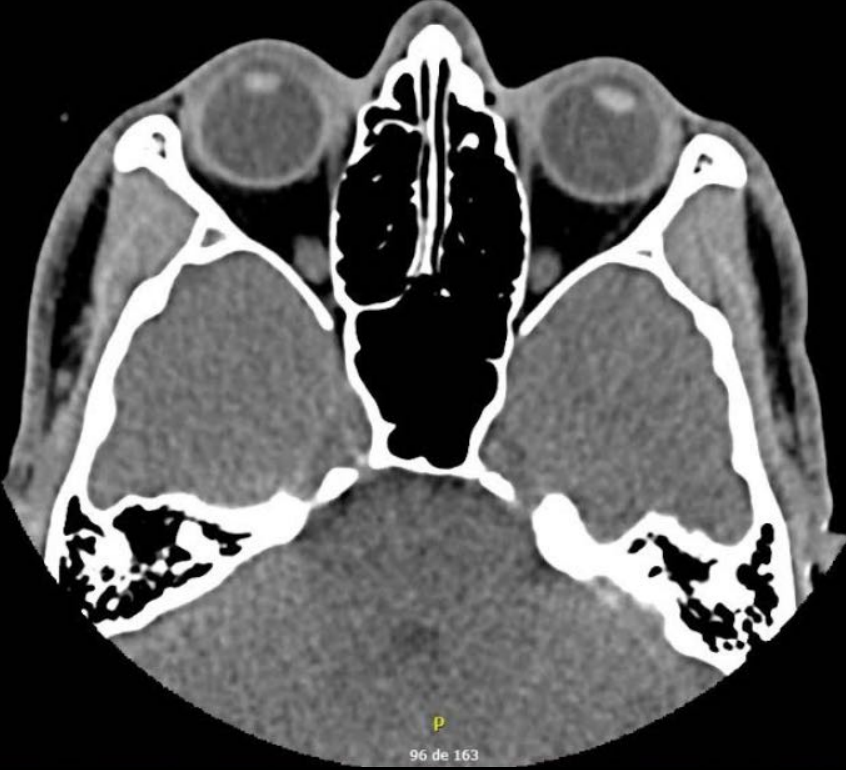
Clinical case

Talitha Borges Aguiar, MD

Retina and Vitreous Fellowship

- Male, 27yo
- Piercing eye injury nailing a nail into a wooden fence 4 days ago.
- Wound sutured by the Cornea and Anterior Segment Diseases department 4 days ago.
- CT scan didn't indicate any foreign body.
- No other personal or family history.

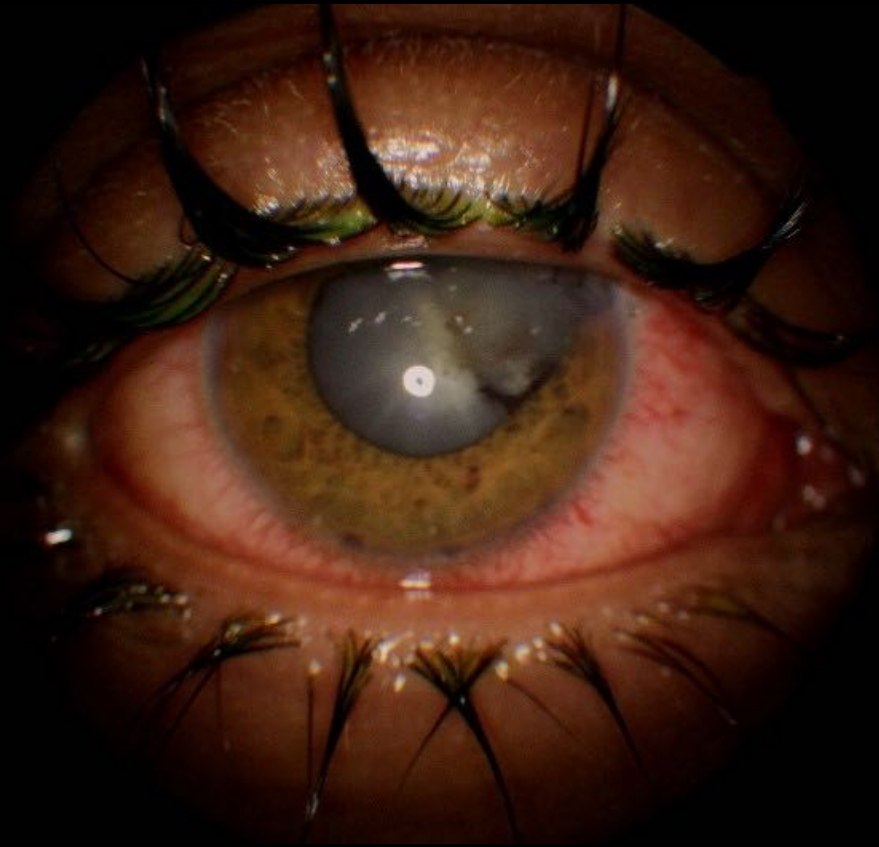
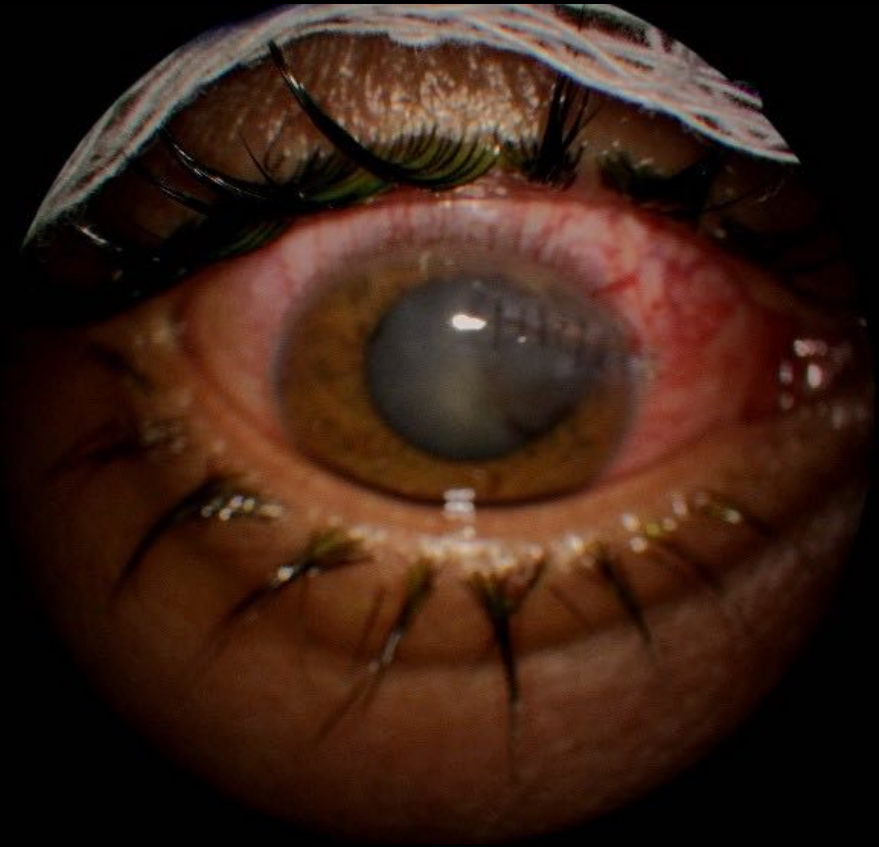CT scan showing no foreign body



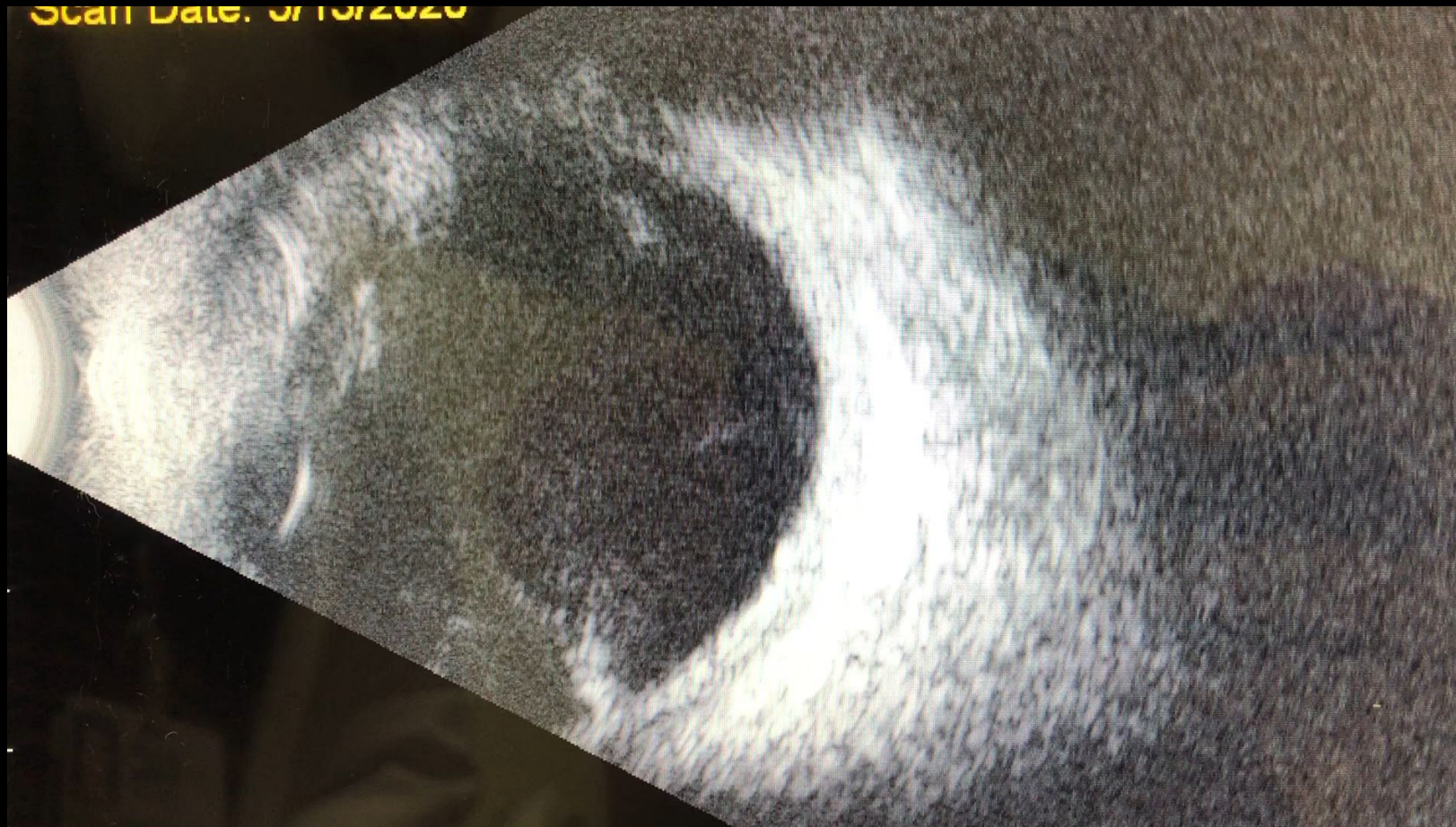
Visual acuity

OD: HM; OS: 20/20

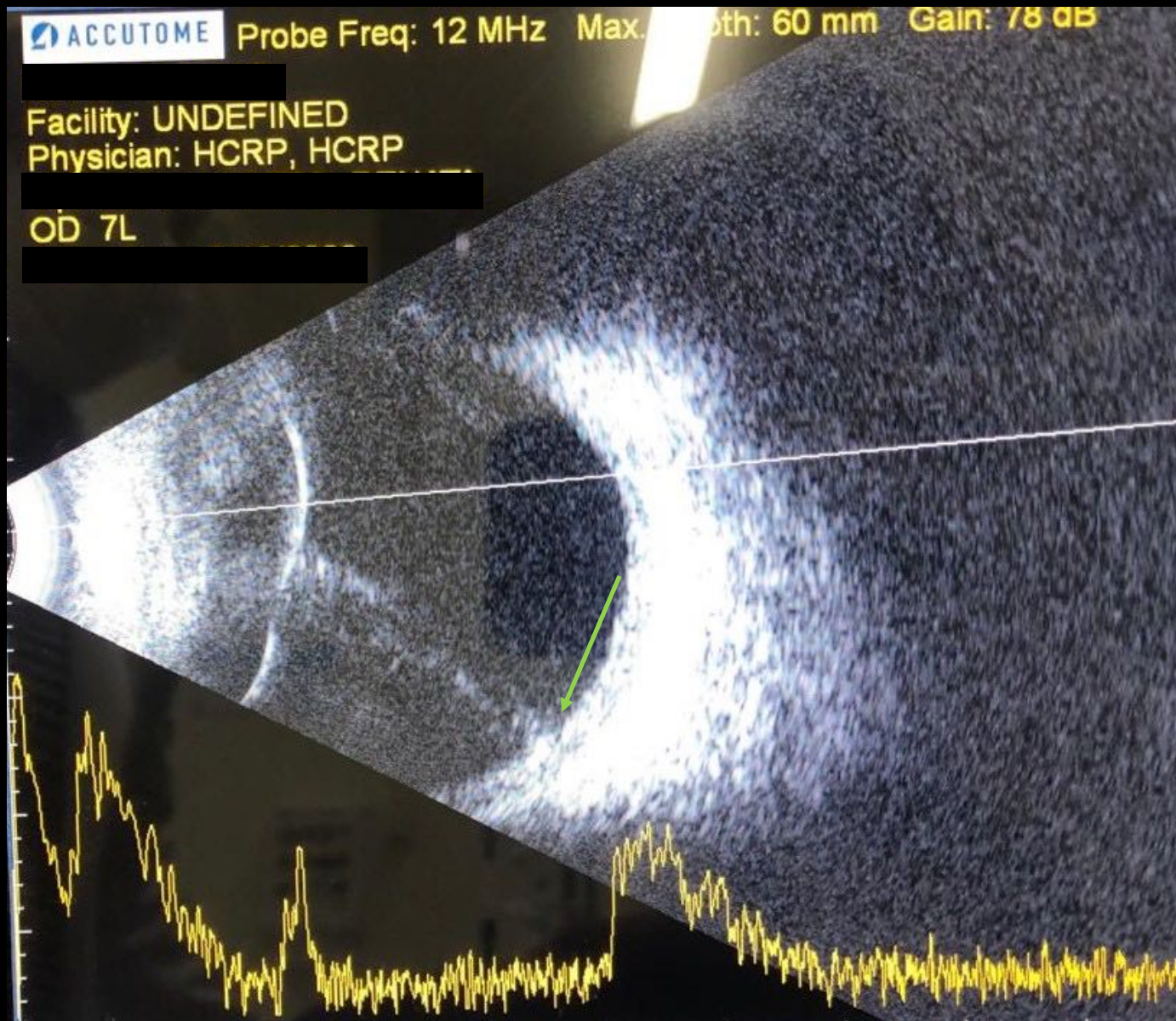
IOP OD: 12; OS: 13



Hyperechogenic lesion (wood?)



Hyperechogenic lesion (wood?)



Intraocular foreign body

Management: Vitrectomy

VA OD: 20/50; OS: 20/20

