

---

# Caso Cirúrgico

*Dr. Annelise Nicotti*



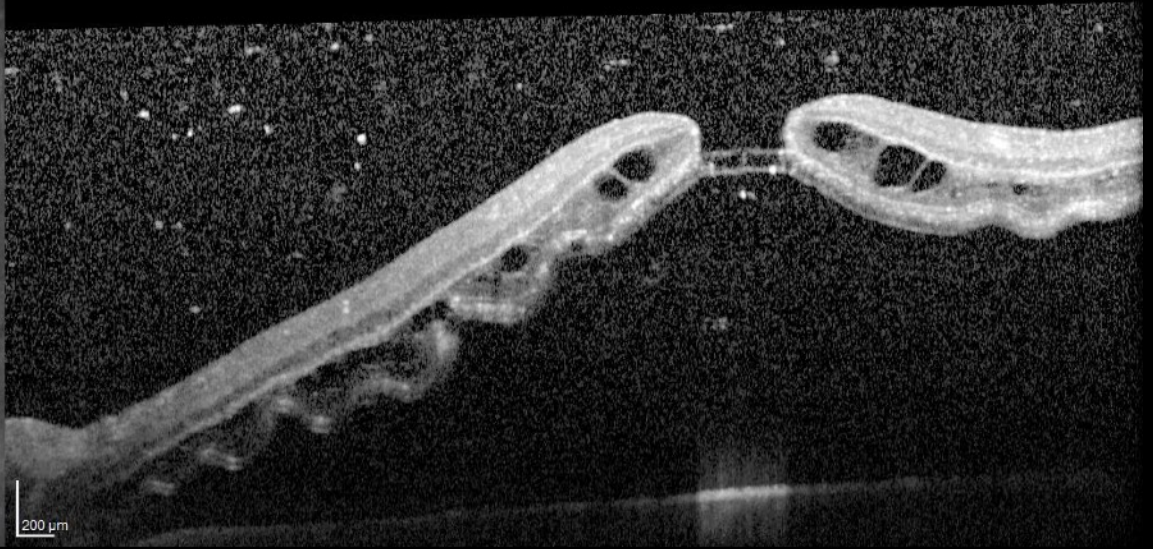
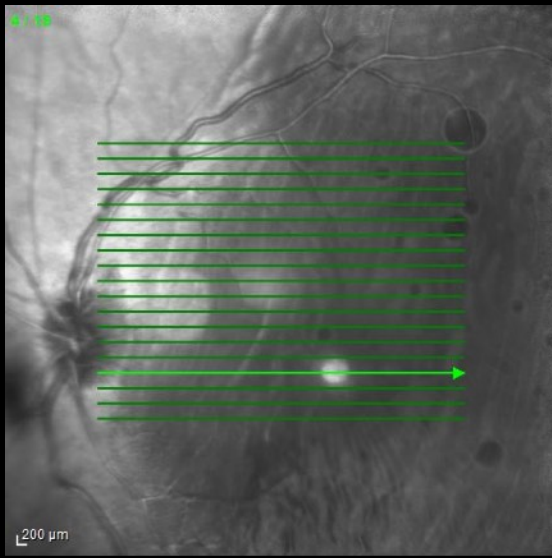
---

04/06/2019

- DAGL, feminino, 59 anos.
- BAV súbita em OE há 1 semana.
- HOP: FACO OD em 2012 e OE em 2016.
- HMP: nega comorbidades.

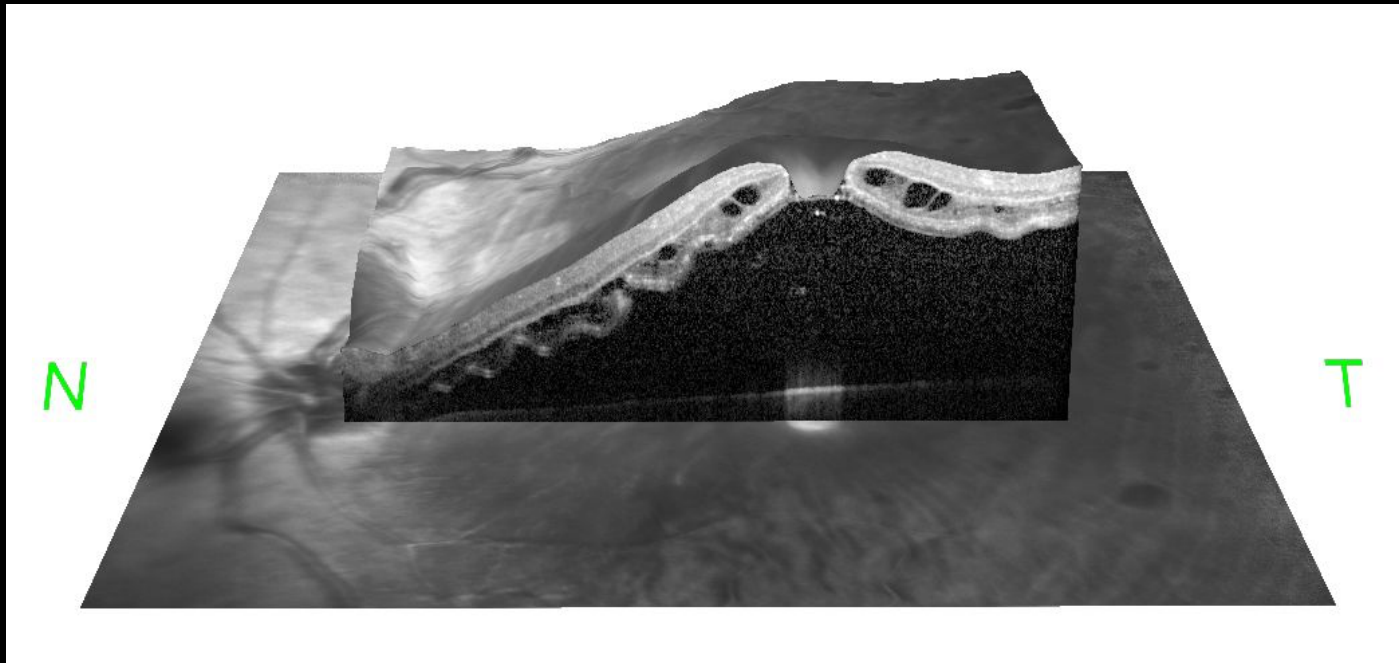
---

	OD	OE
AV	20/25	CD 1m
TONO	18 mmHg	12 mmHg
BIO	córnea clara, CA ampla, sem RCA, íris trófica, pseudofácica.	córnea clara, CA ampla, sem RCA, íris trófica, pseudofácica.
FO	retina aplicada, periferia sem alterações aparentes, mácula trófica.	descolamento de retina regmatogênico com rotura temporal.

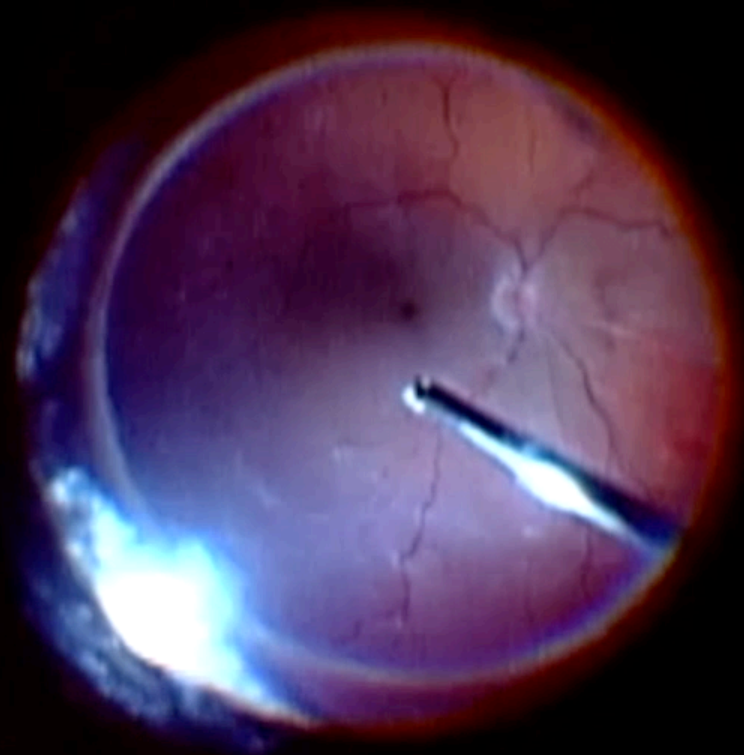


04/06/2019, OS  
IR&OCT 30° ART [HR] ART(25) Q: 15

HEIDELBERG  
ENGINEERING



- 
- Impressão: DR regmatogênico com BM.
  - Conduta:
    - Indicada cirurgia de VPP + Peeling de MLI.



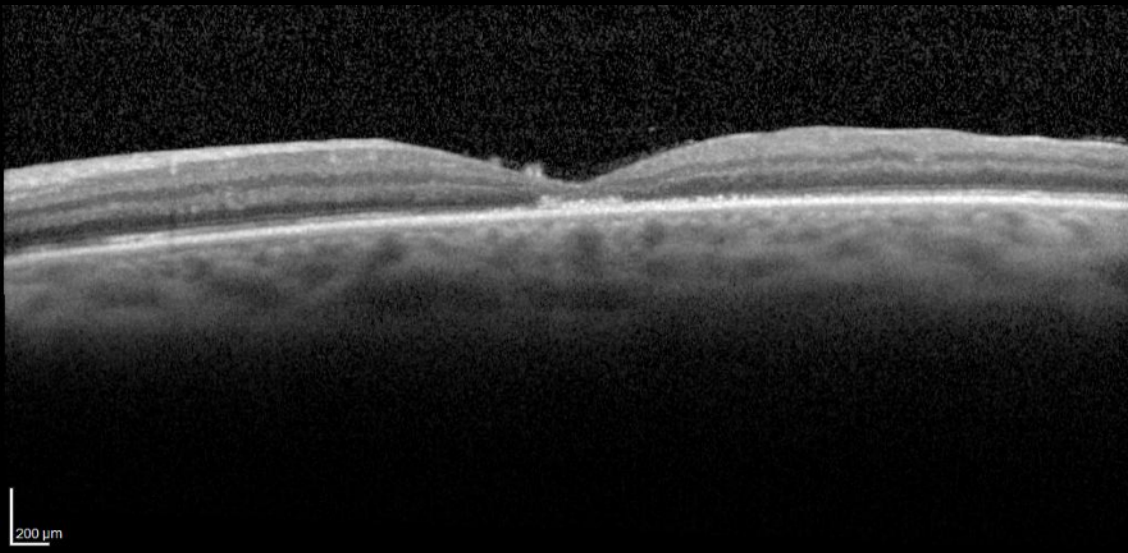
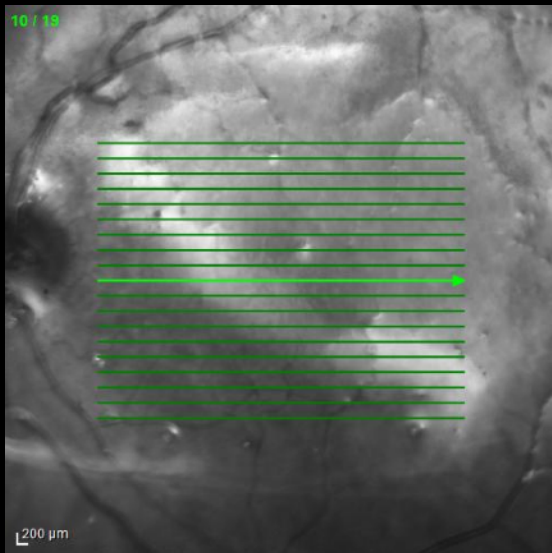
---

10/06/2019

- Realizada cirurgia em OE.

02/07/2019


- 3 semanas de pós-op
- AV OE CD 2m.
- OCT com fechamento do BM.



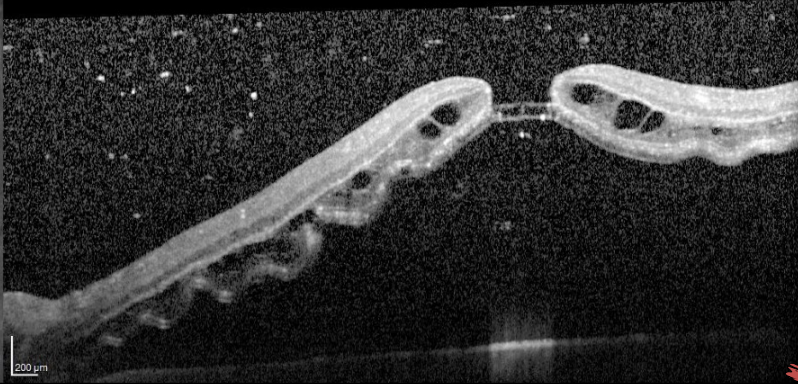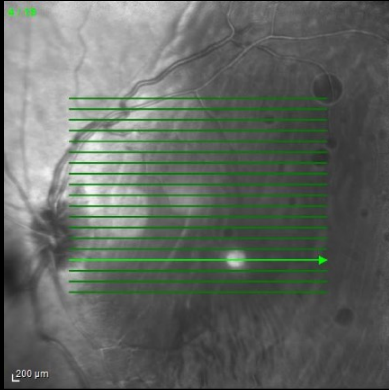
02/07/2019, OS

IR&OCT 30° ART [HR] ART(24) Q: 28

HEIDELBERG  
ENGINEERING

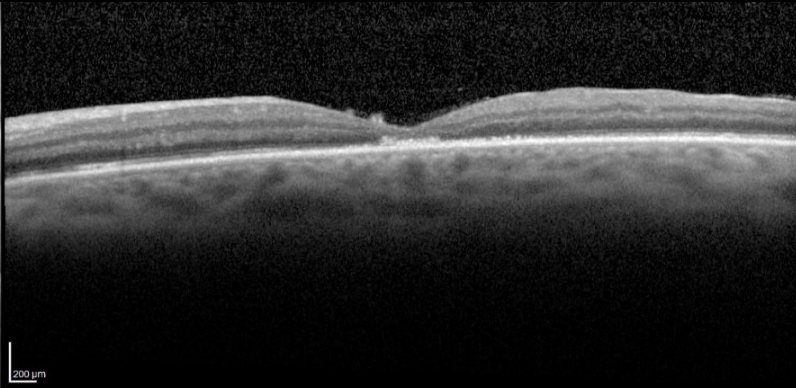
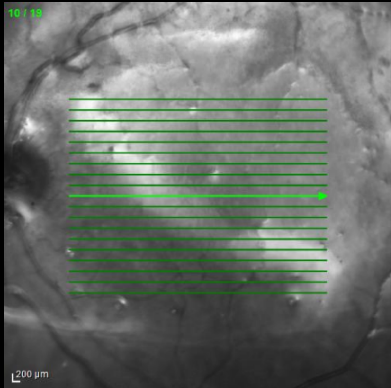






HEIDELBERG  
ENGINEERING

VPP + Peeling MLI + OSi



HEIDELBERG  
ENGINEERING

*Obrigada!*

