

---

# Caso Cirúrgico

*E2 Annelise Nicotti*

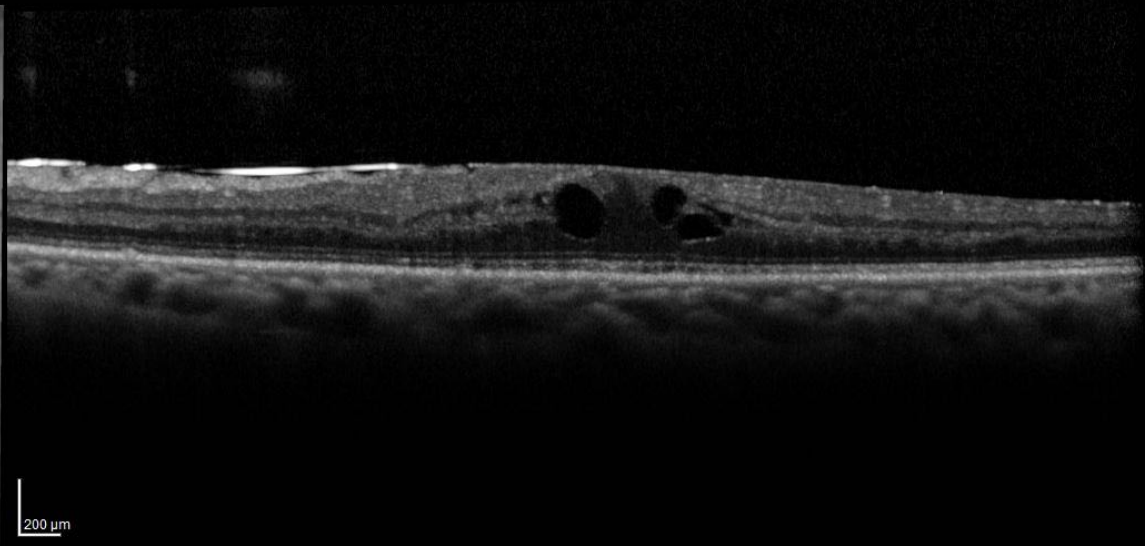
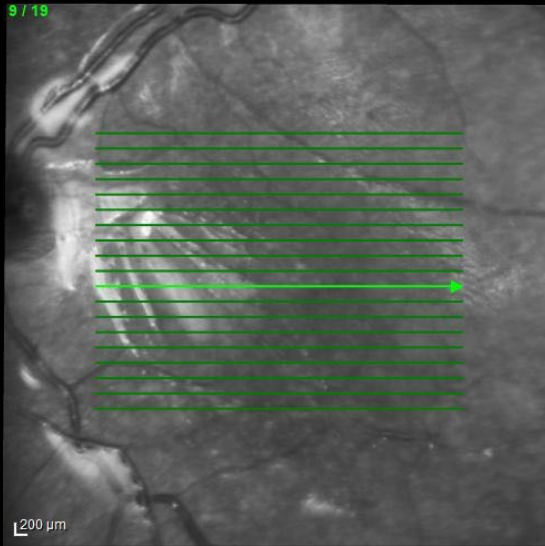


27/01/2020

- OJC, masculino, 65 anos.
- Vem em consulta de revisão para avaliar retirada de óleo de silicone intraocular.
- HOP: em novembro 2018 realizou cirurgia de FACO + VPP + OSi em OE devido a DR regmatogênico total.
- HMP: HAS e DPOC.

	OD	OE
AV	20/32	CD 2m (TL +8.50)
TONO	15 mmHg	13 mmHg
BIO	córnea clara, CA ampla, sem RCA, íris trófica, catarata N1 + cortical.	córnea clara, ausência de OSi em CA, CA ampla, sem RCA, íris trófica, pseudofácico.
FO	retina aplicada, periferia sem alterações aparentes, mácula trófica.	OSi, retina aplicada, laser 360° em periferia bem pigmentado, roturas bem cercadas, MER em polo posterior com distorção foveal.

9 / 19

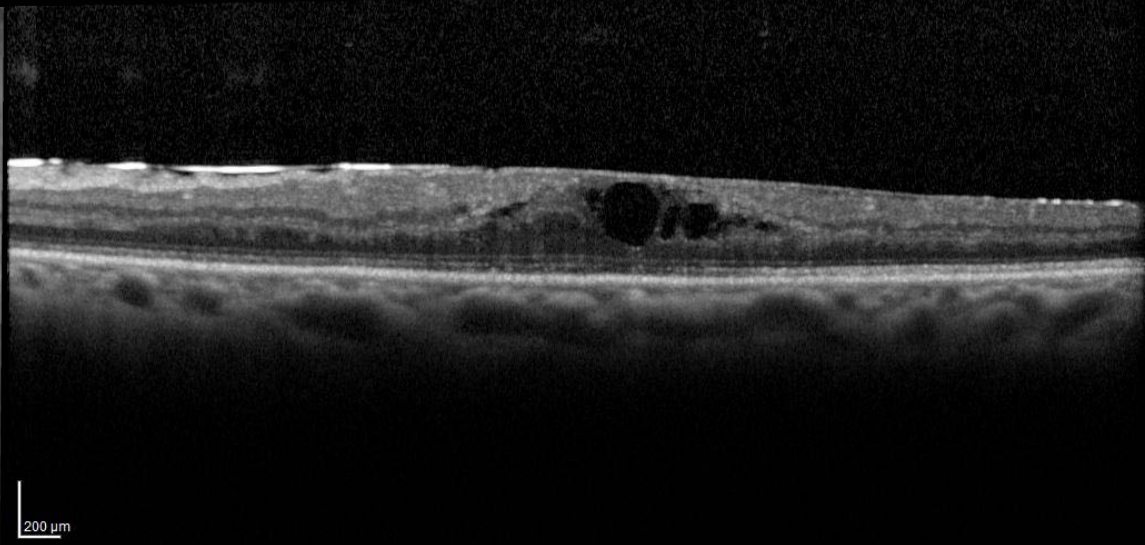
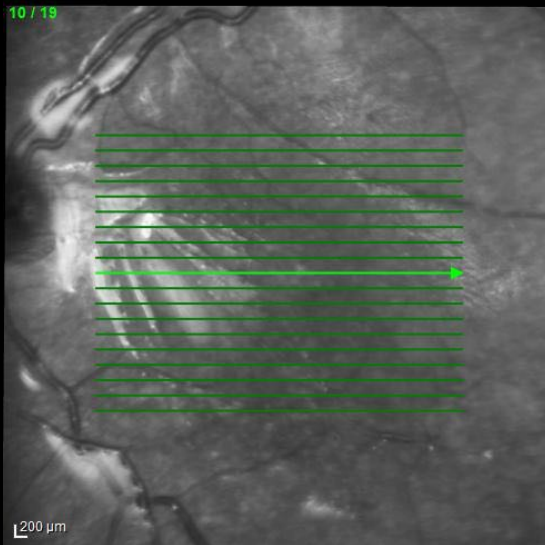


27/01/2020, OS

IR&OCT 30° ART [HR] ART(25) Q: 42

HEIDELBERG  
Engineering

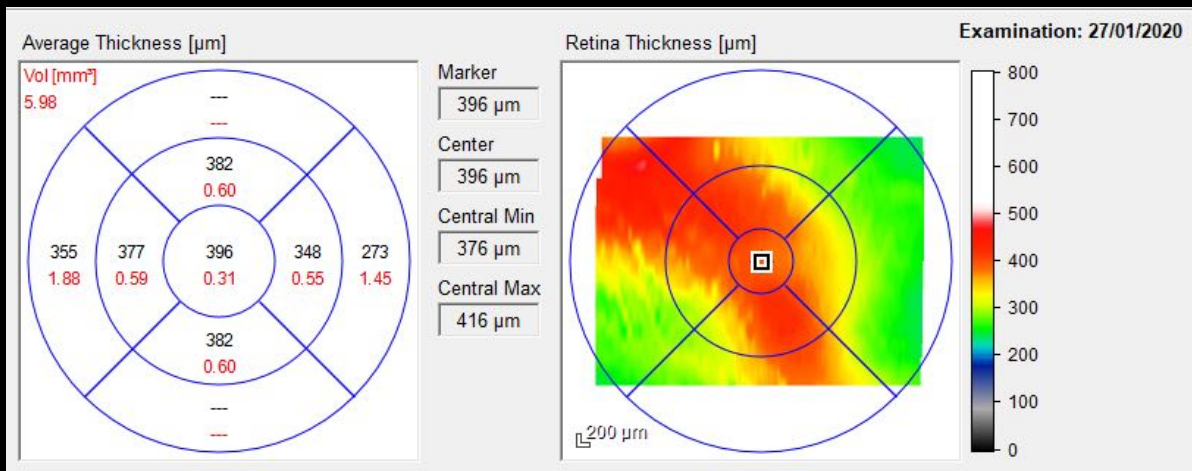
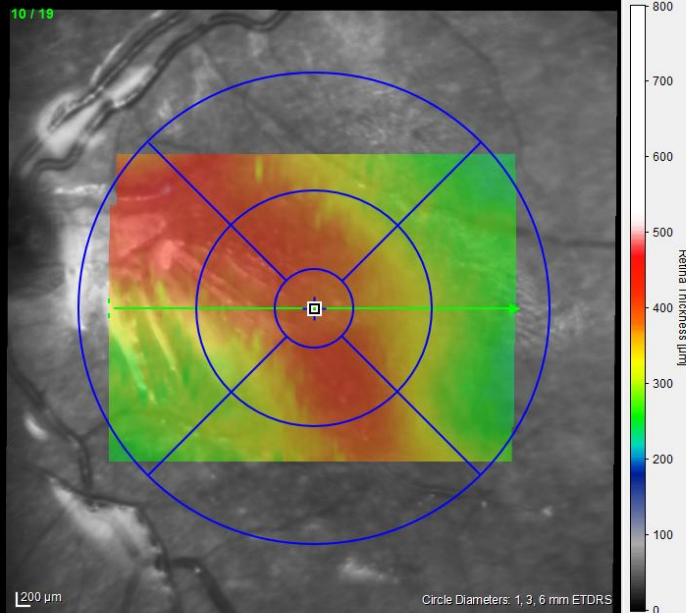
10 / 19



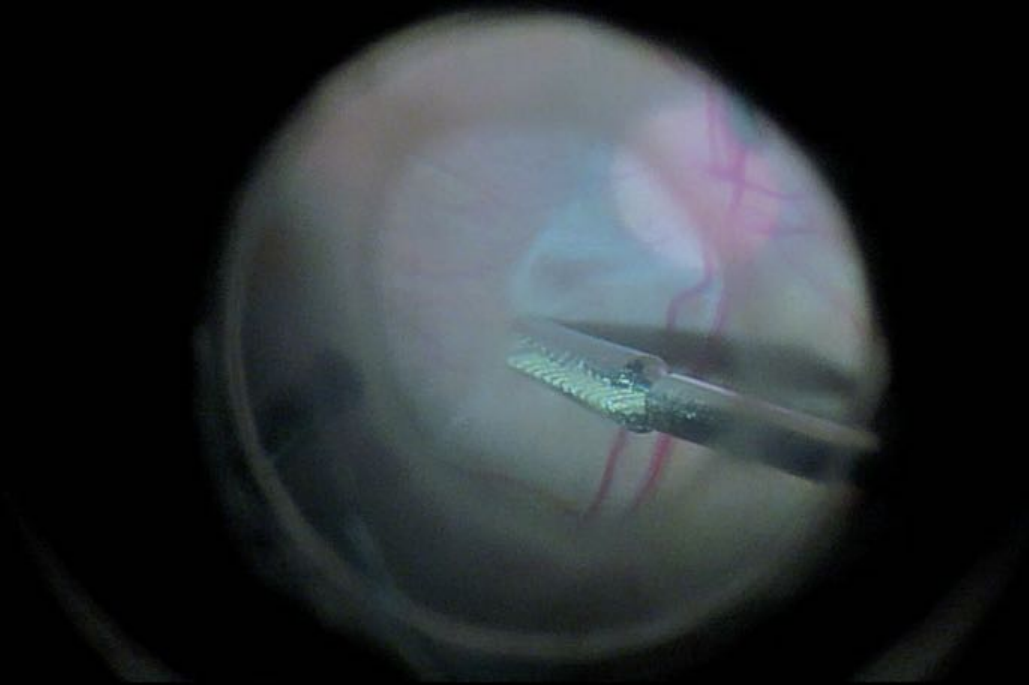
27/01/2020, OS

IR&OCT 30° ART [HR] ART(25) Q: 40

HEIDELBERG  
Engineering



- 
- Impressão: MER com distorção foveal.
  - Conduta:
    - Indicada cirurgia de retirada de OSi sob visualização com peeling de MER.



---

06/03/2020

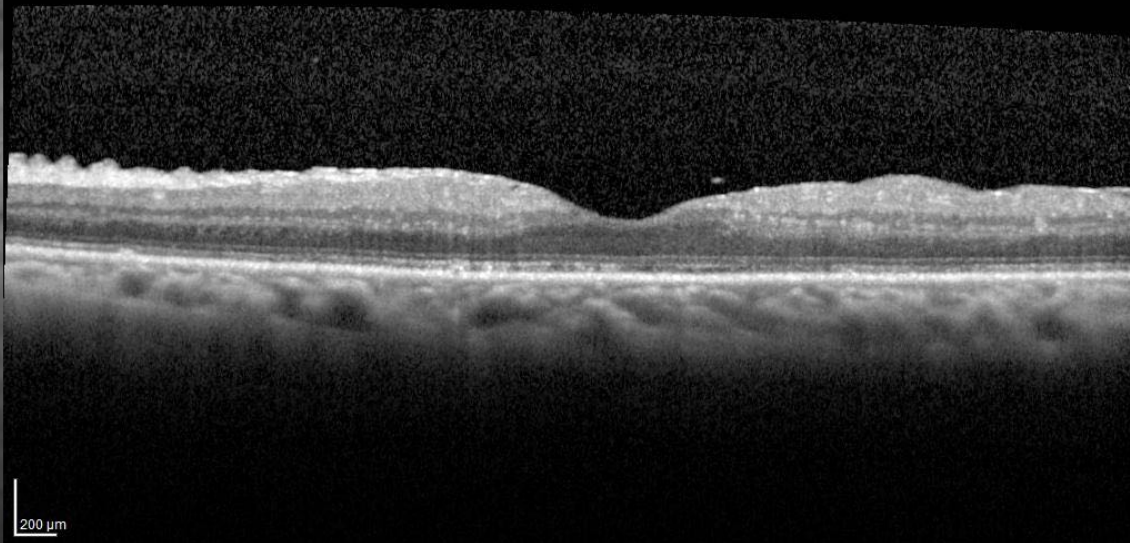
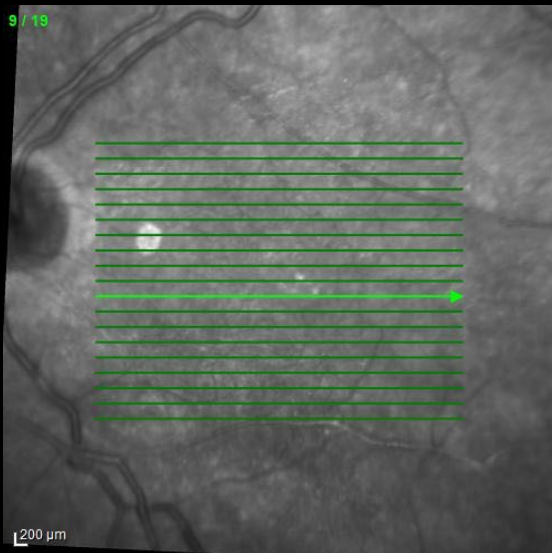
- Realizada cirurgia em OE.

14/05/2020

- 2 meses de pós-op
- AV OE 20/60 (TL +3.50).
- OCT com melhora importante.



9 / 19

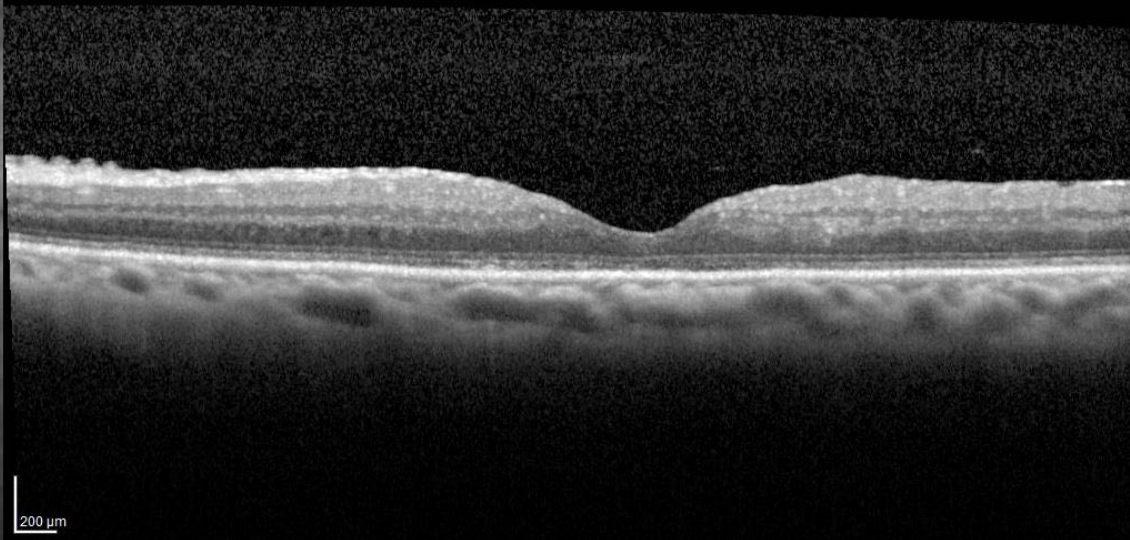
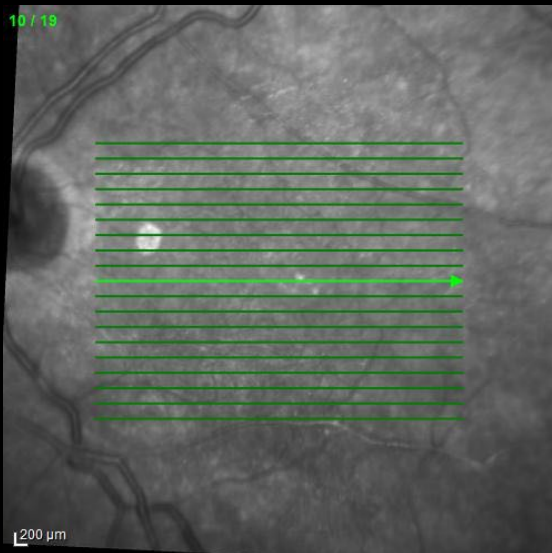


14/05/2020, OS

IR&OCT 30° ART [HR] ART(25) Q: 23

HEIDELBERG  
Engineering

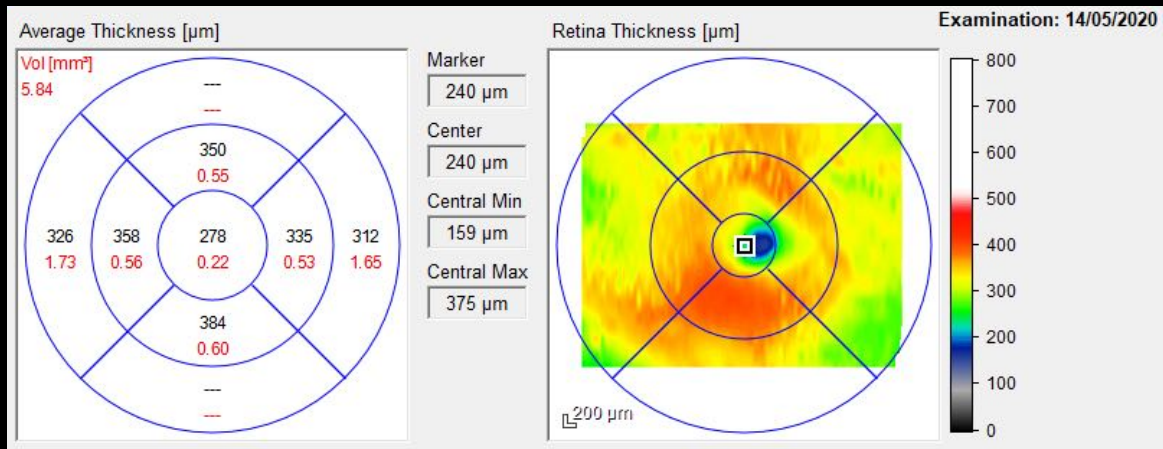
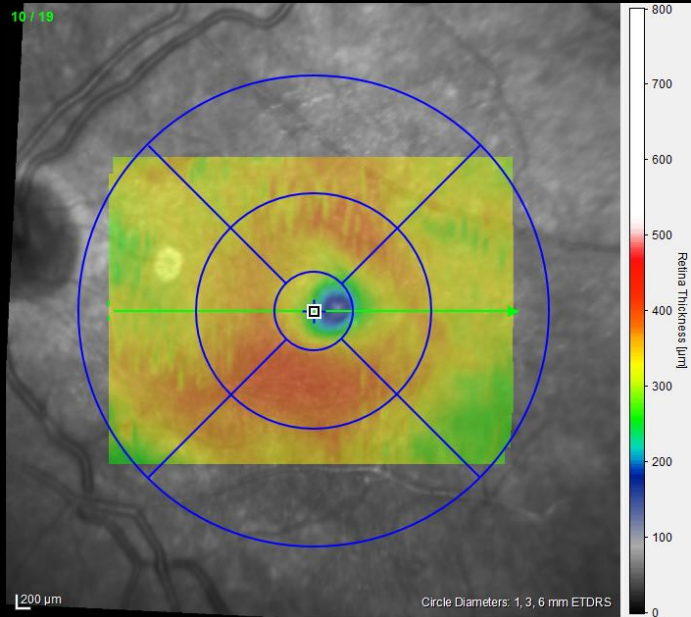
10 / 19

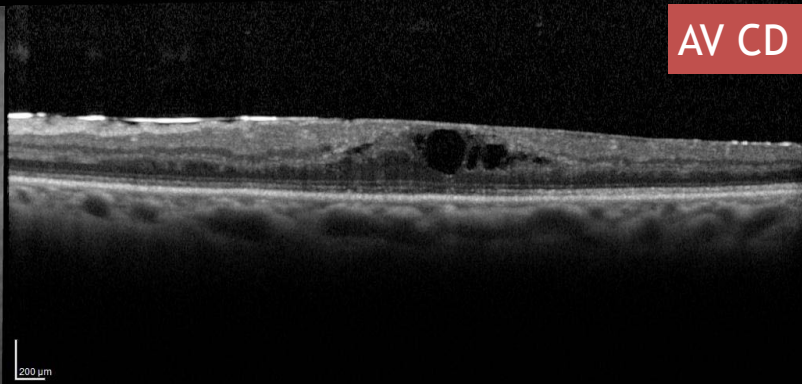
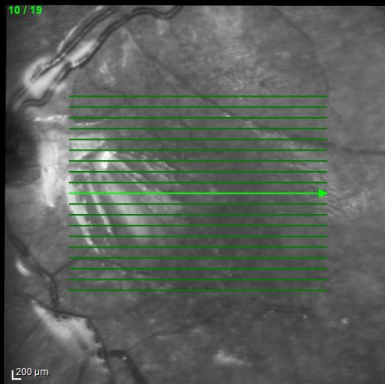


14/05/2020, OS

IR&OCT 30° ART [HR] ART(25) Q: 28

HEIDELBERG  
Engineering



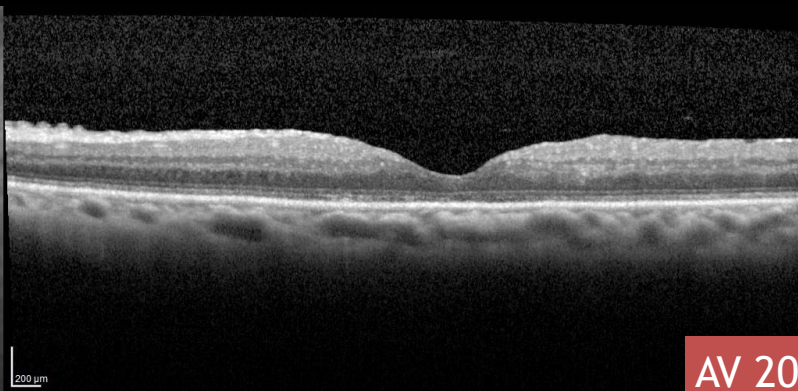
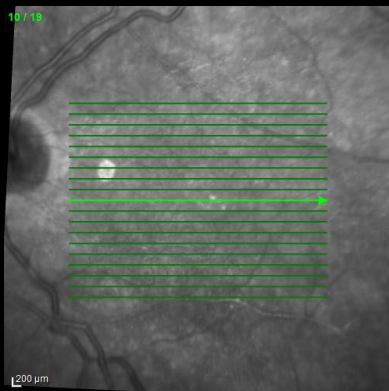


AV CD 2m (TL +8.50)

27/01/2020\_OS  
IR&OCT 30° ART [HR] ART(25) Q: 40

HEIDELBERG  
ENGINEERING

Ret Osi + Peeling MER



AV 20/60 (TL +3.50)

14/05/2020\_OS  
IR&OCT 30° ART [HR] ART(25) Q: 28

HEIDELBERG  
ENGINEERING

---

# Obrigada

*82 Annelise Nicotti*

